

# NOVEL APPROACH TO FOREFOOT RECONSTRUCTION (primary and revision)

***NO METAL, NO PROBLEM***

**Daniel S. Schulman, DPM, FACFAS**  
Bio Family Clinic, Inc. / Yuma, AZ

**[dr.dan@justboneimplants.com](mailto:dr.dan@justboneimplants.com)**  
IG: **@footdocdan**



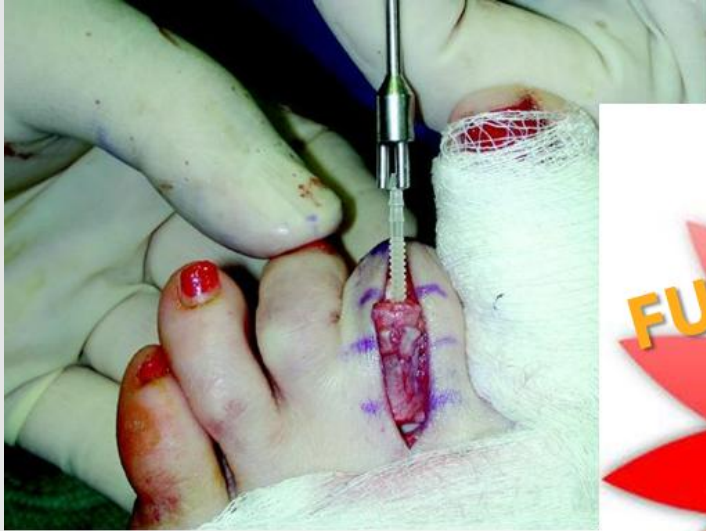**[www.justboneimplants.com](http://www.justboneimplants.com)**

A photograph of a wooden workbench. In the center, a hammer with a black head and an orange handle with a black grip lies on a wooden plank. To the left of the hammer, a pile of light-colored wood shavings is scattered on another plank. In the background, a stack of wooden planks is visible, with a metal drill bit resting on top. The workbench is set on a dark, textured surface, possibly asphalt or concrete.

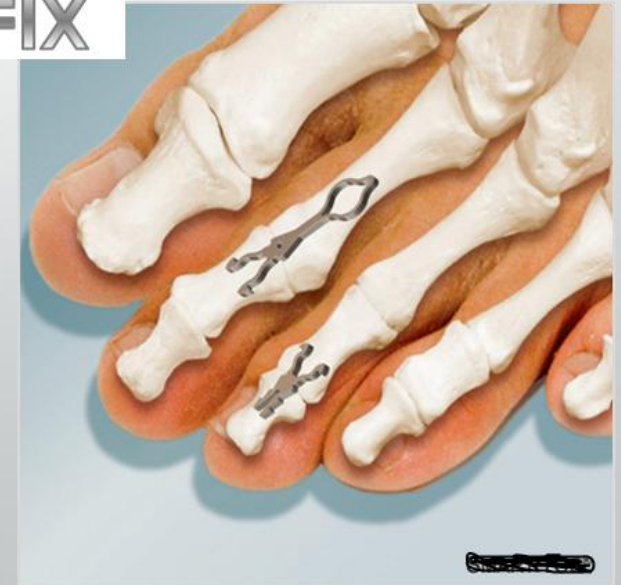
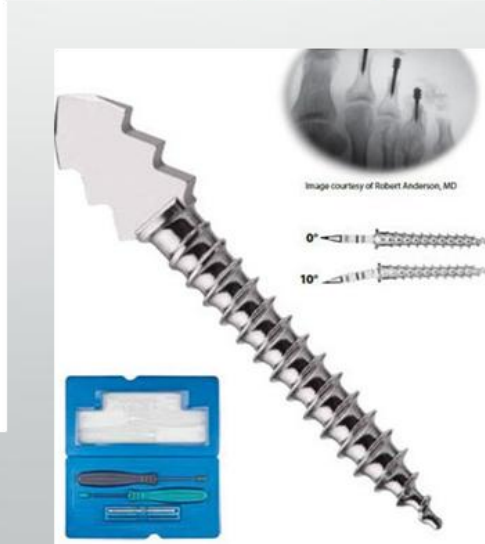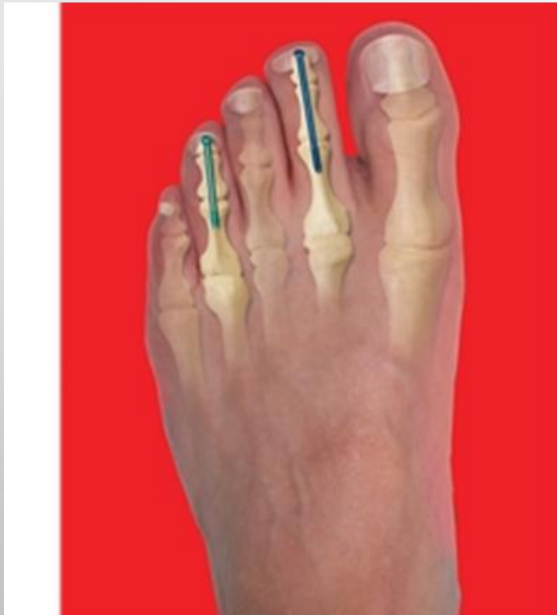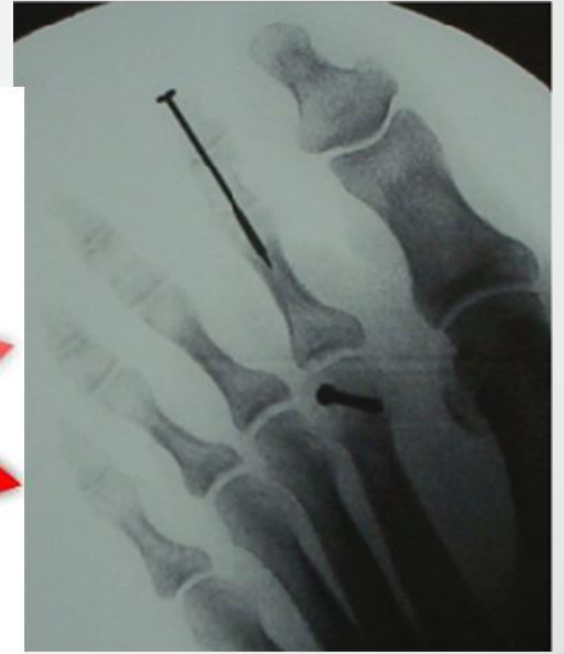# **Disclosures:**

**CEO – Just Bone Orthopedic  
Solutions, LLC**

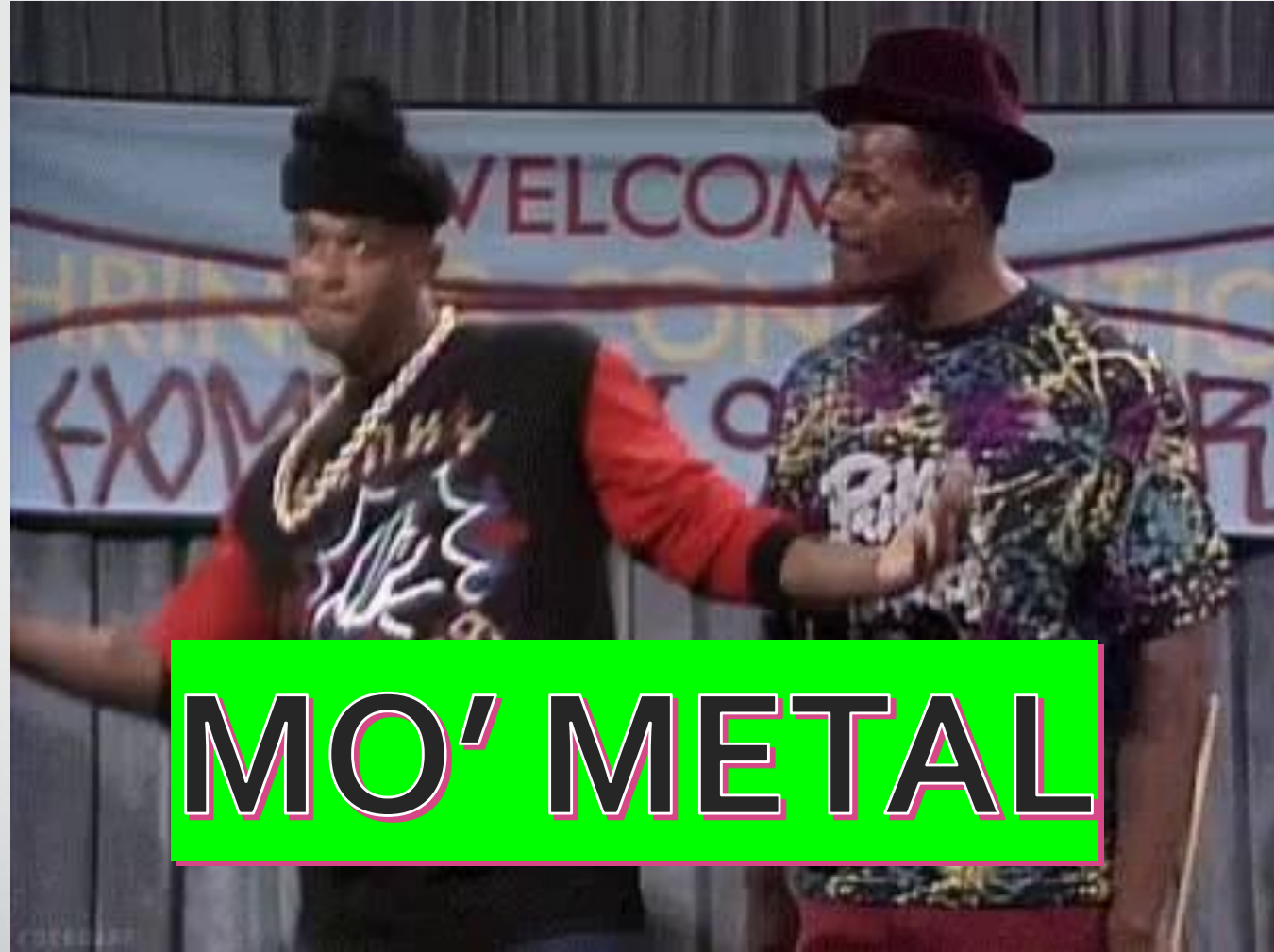**Developer of the AlloMate  
Bone Pin System**



**FUSION** new **FUSION**  
and  
improved  
**HAMMERTOE FIX**



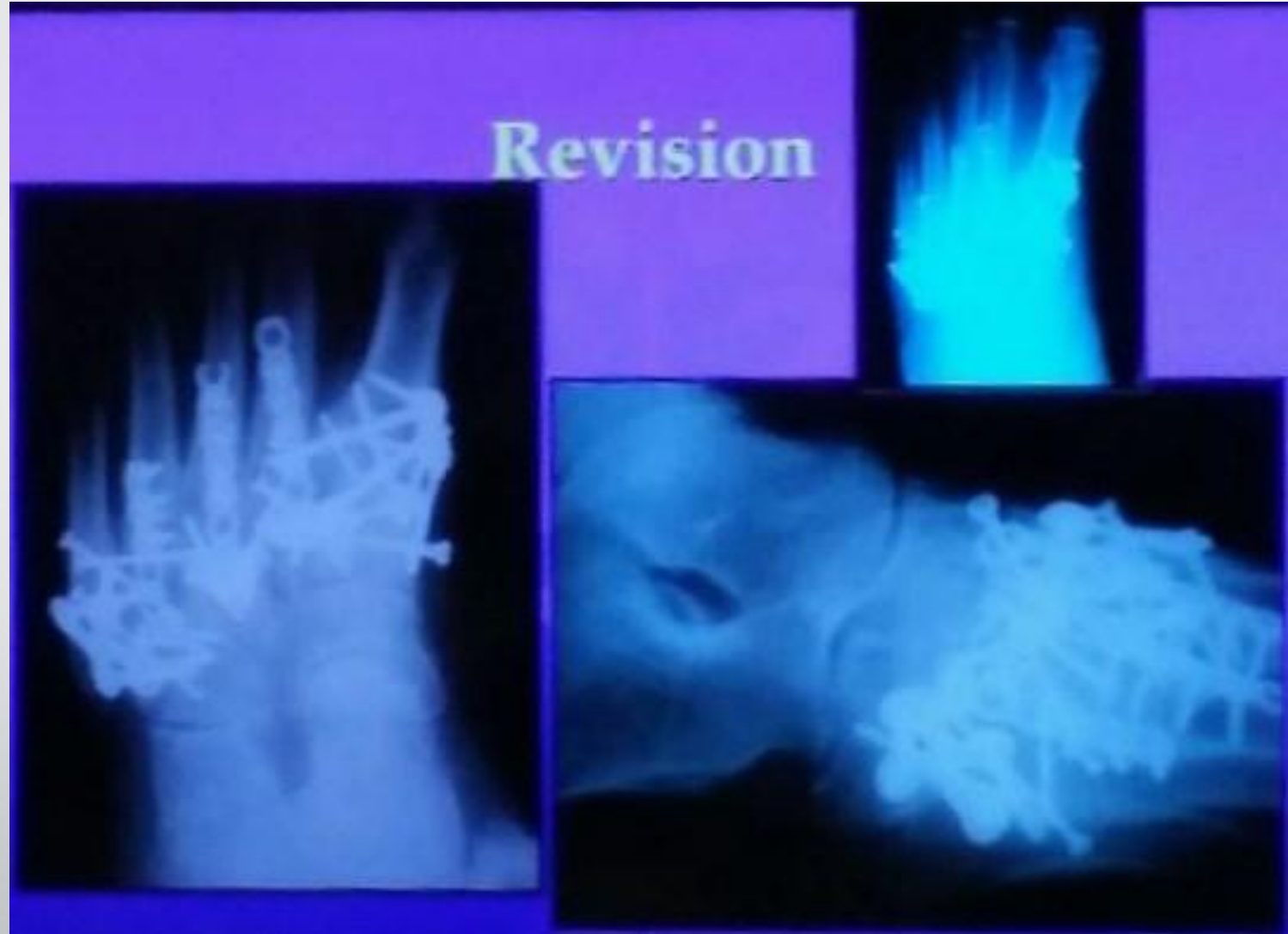



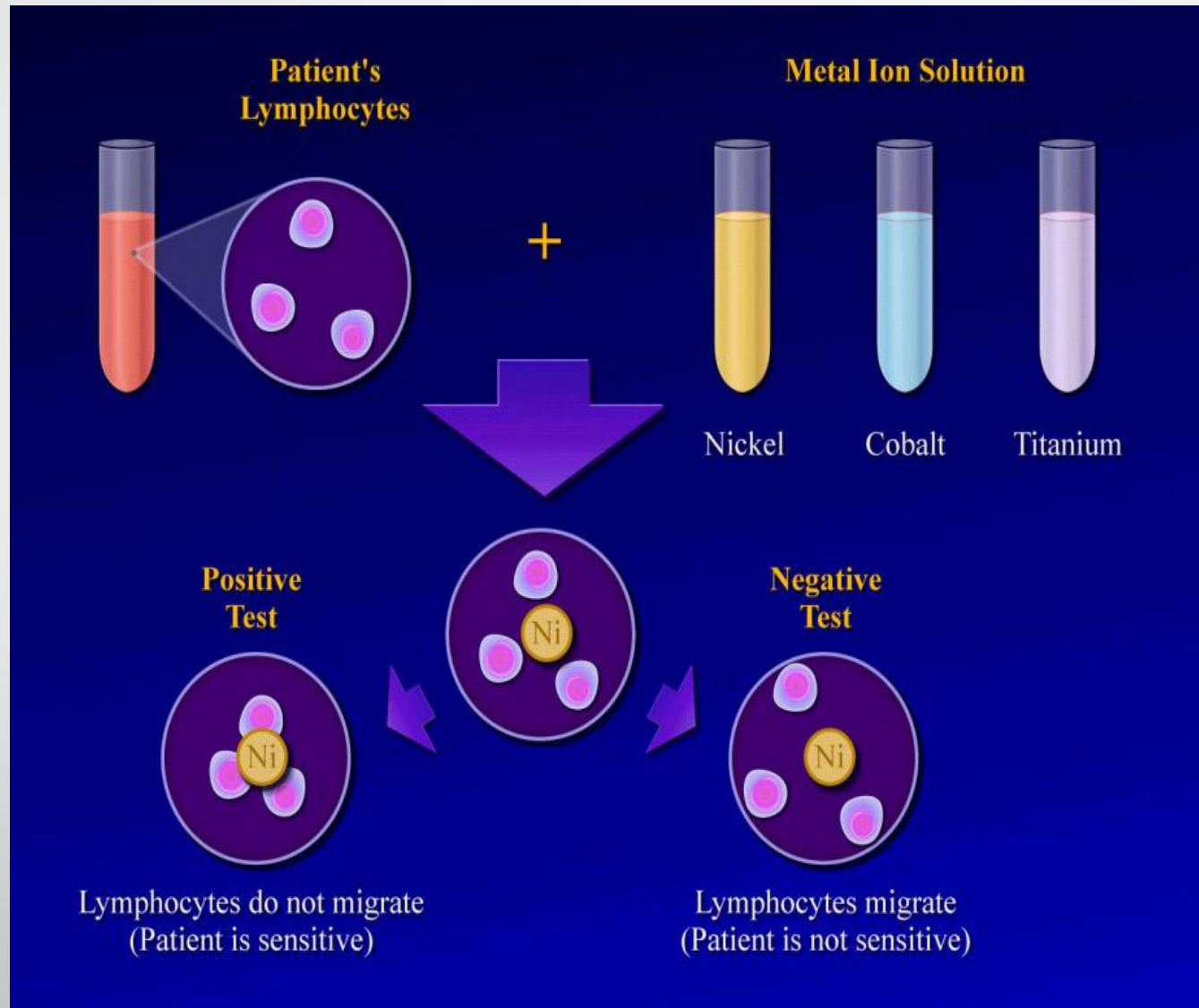
**MO' METAL**



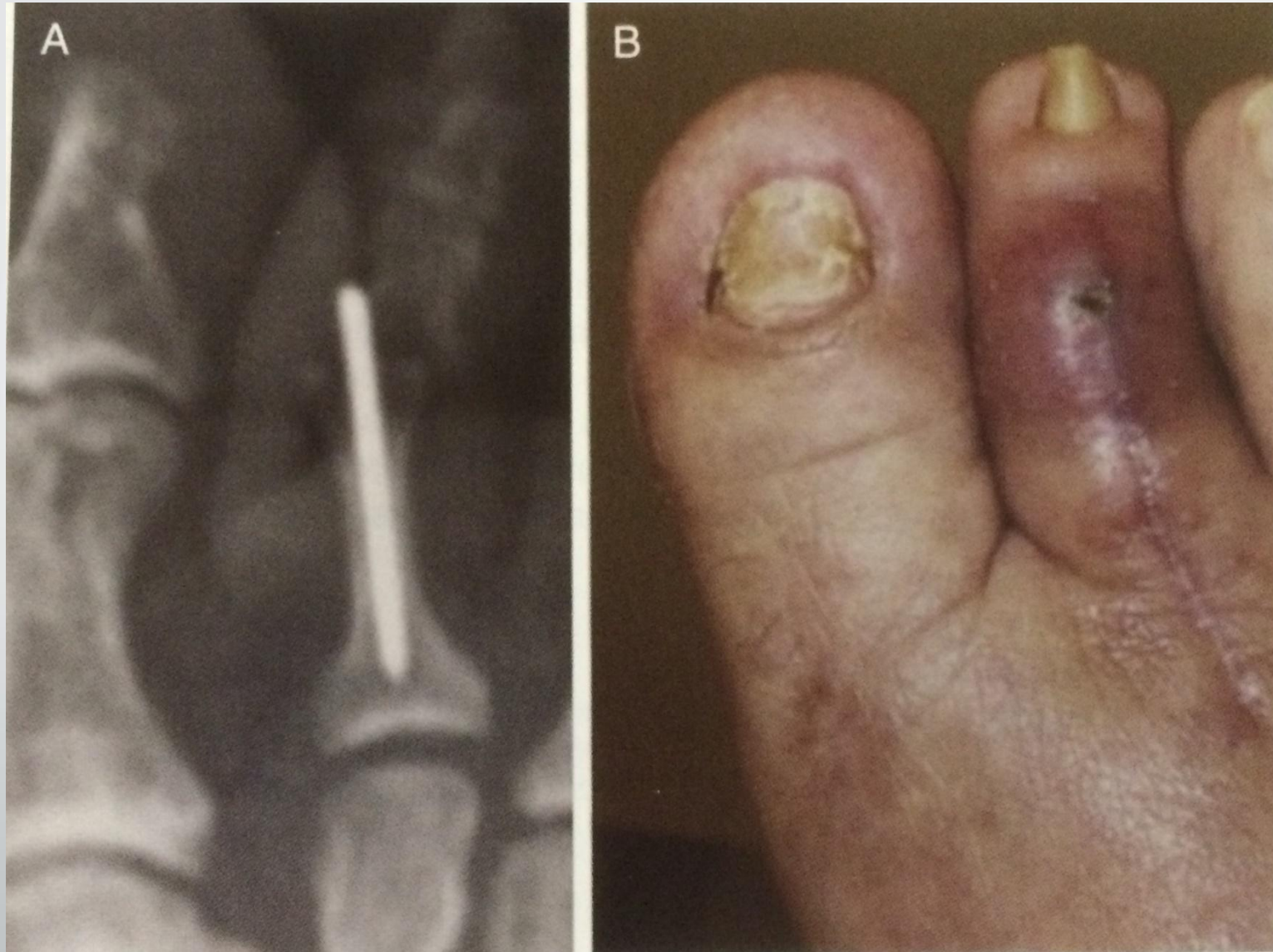
# Got Stress Shielding?



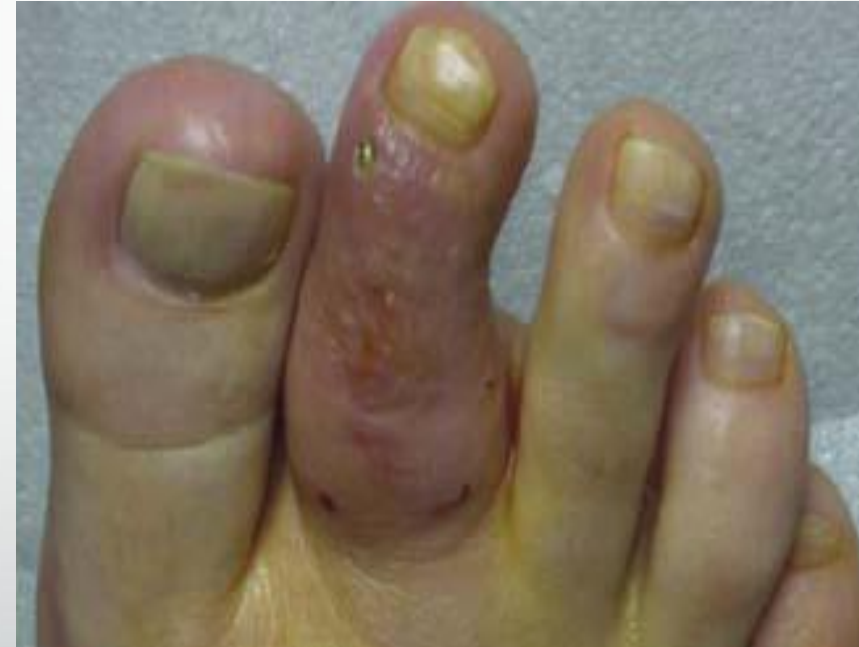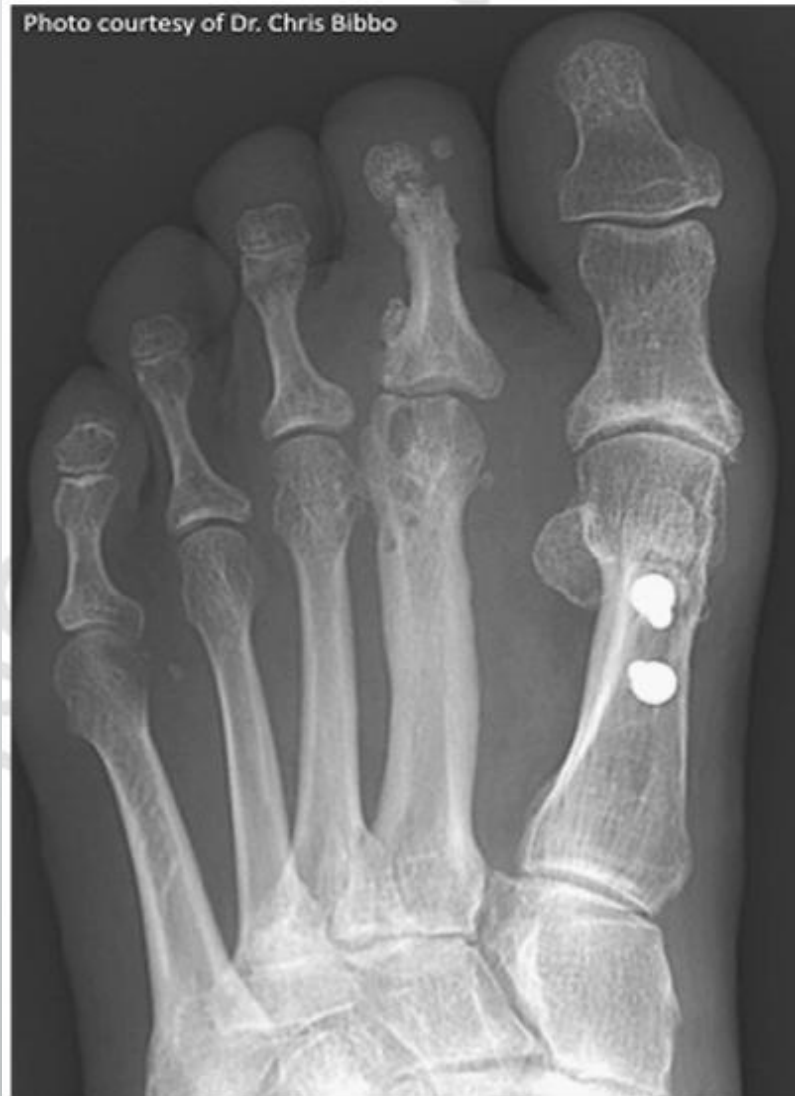# Metallosis



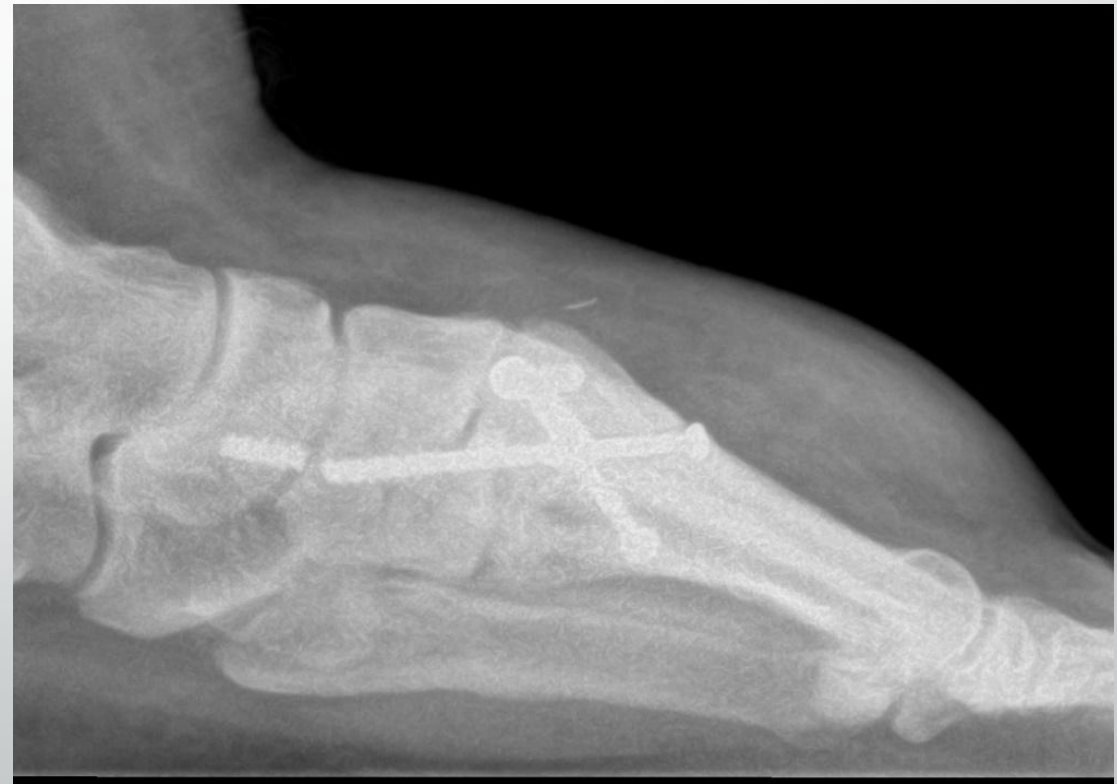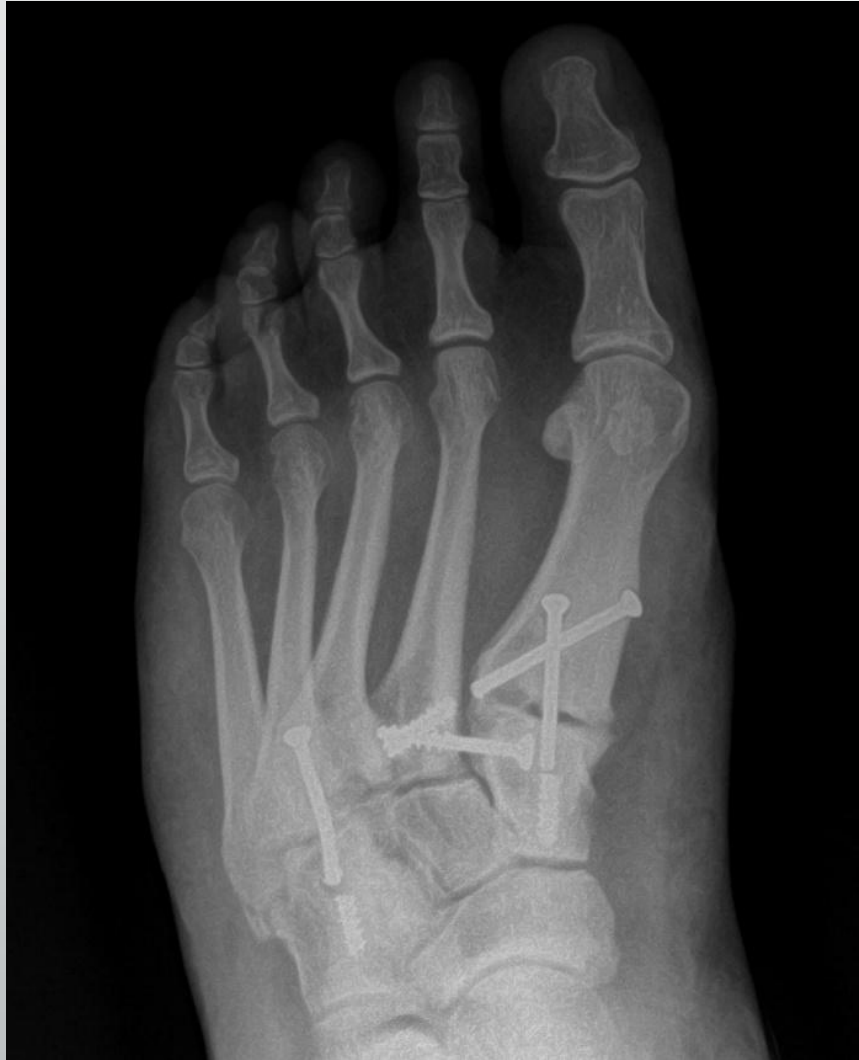# Implant Infection – Possibly



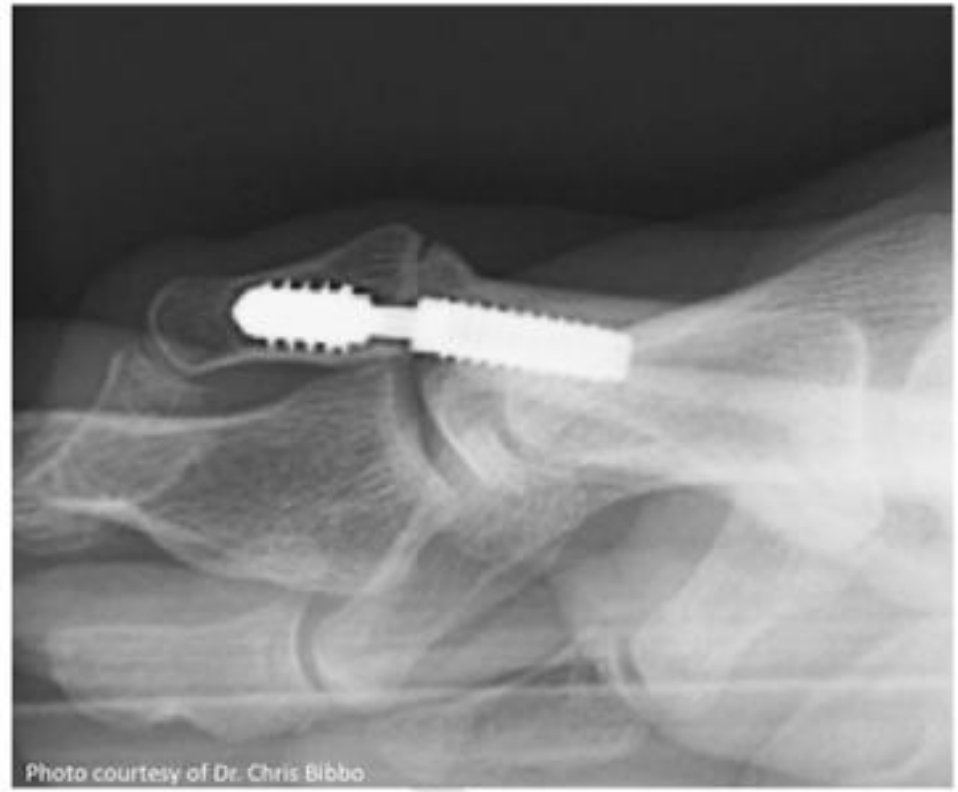
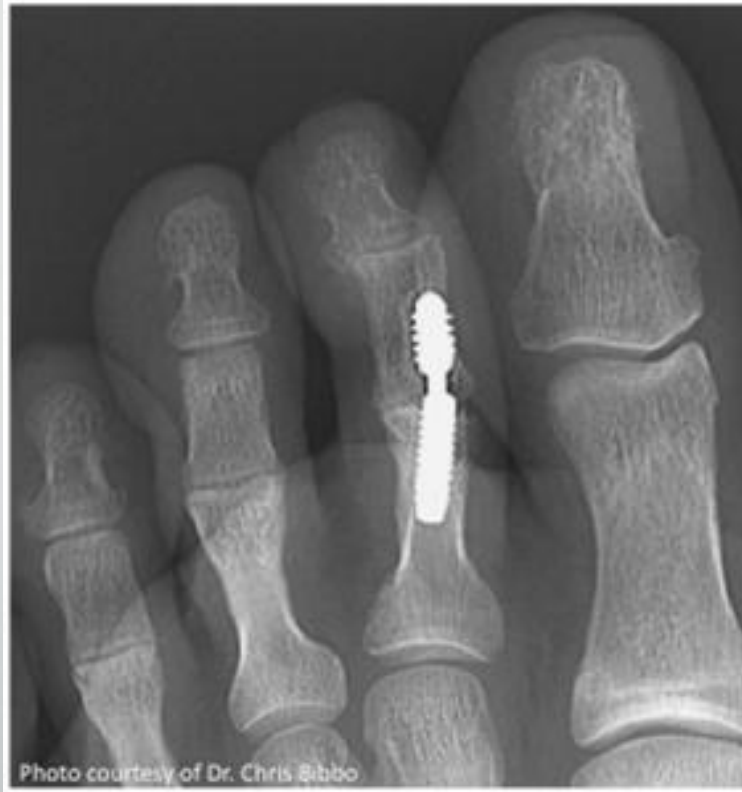# Pin Tract Infection:



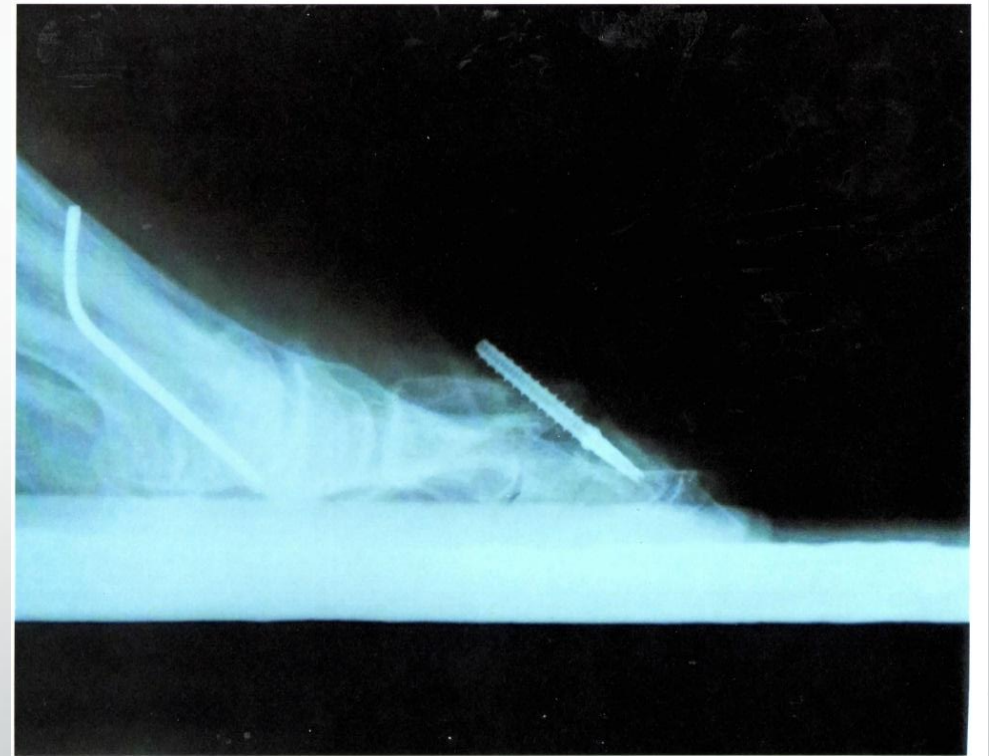
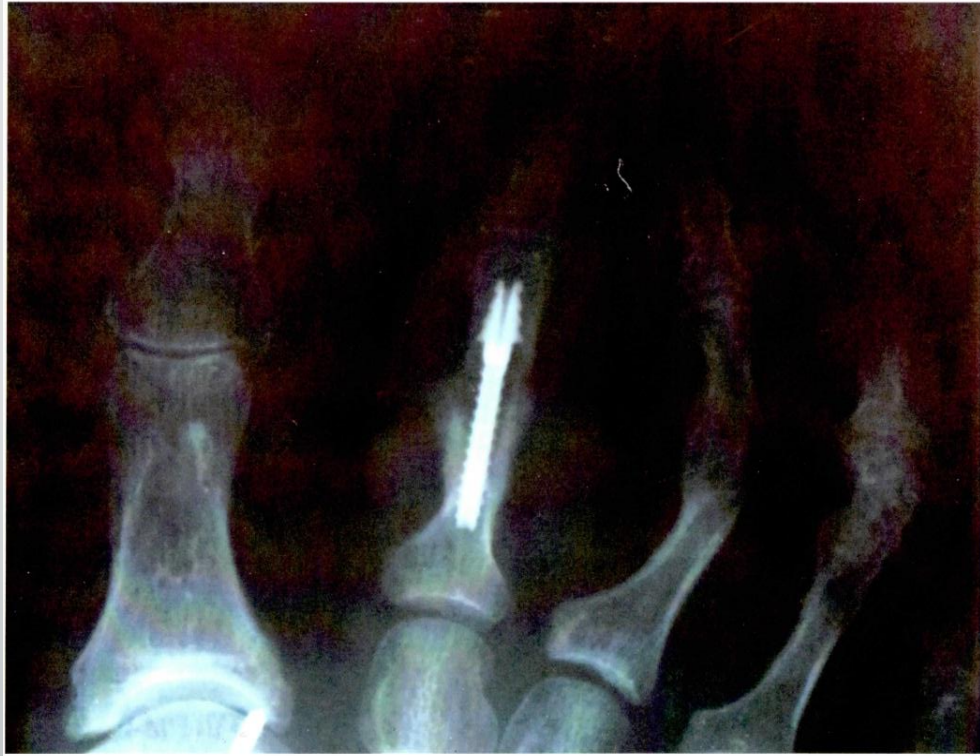# Hardware Failure / Non-union

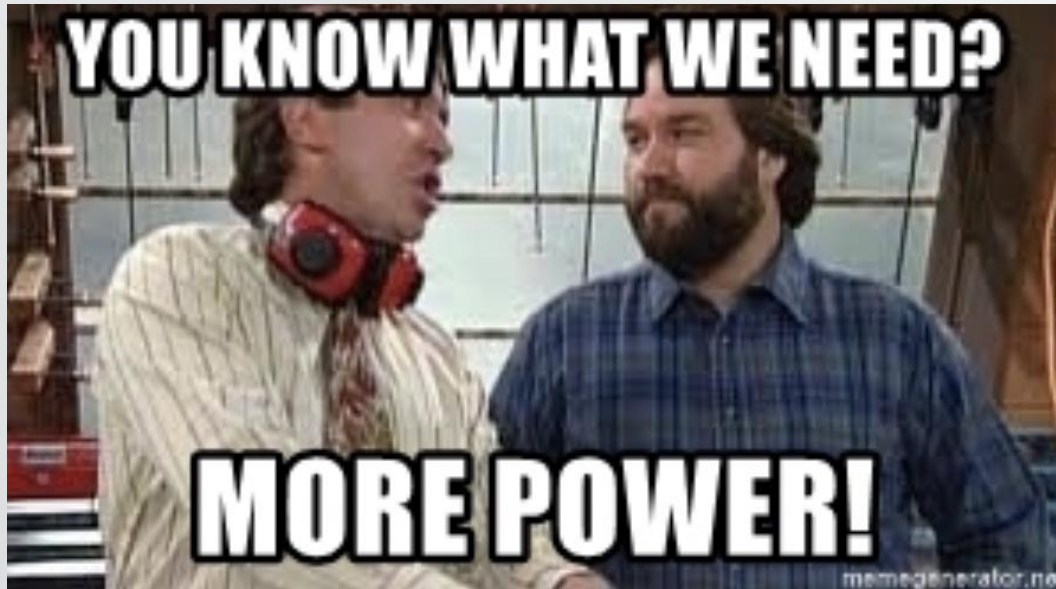

# Malpositioned Implant



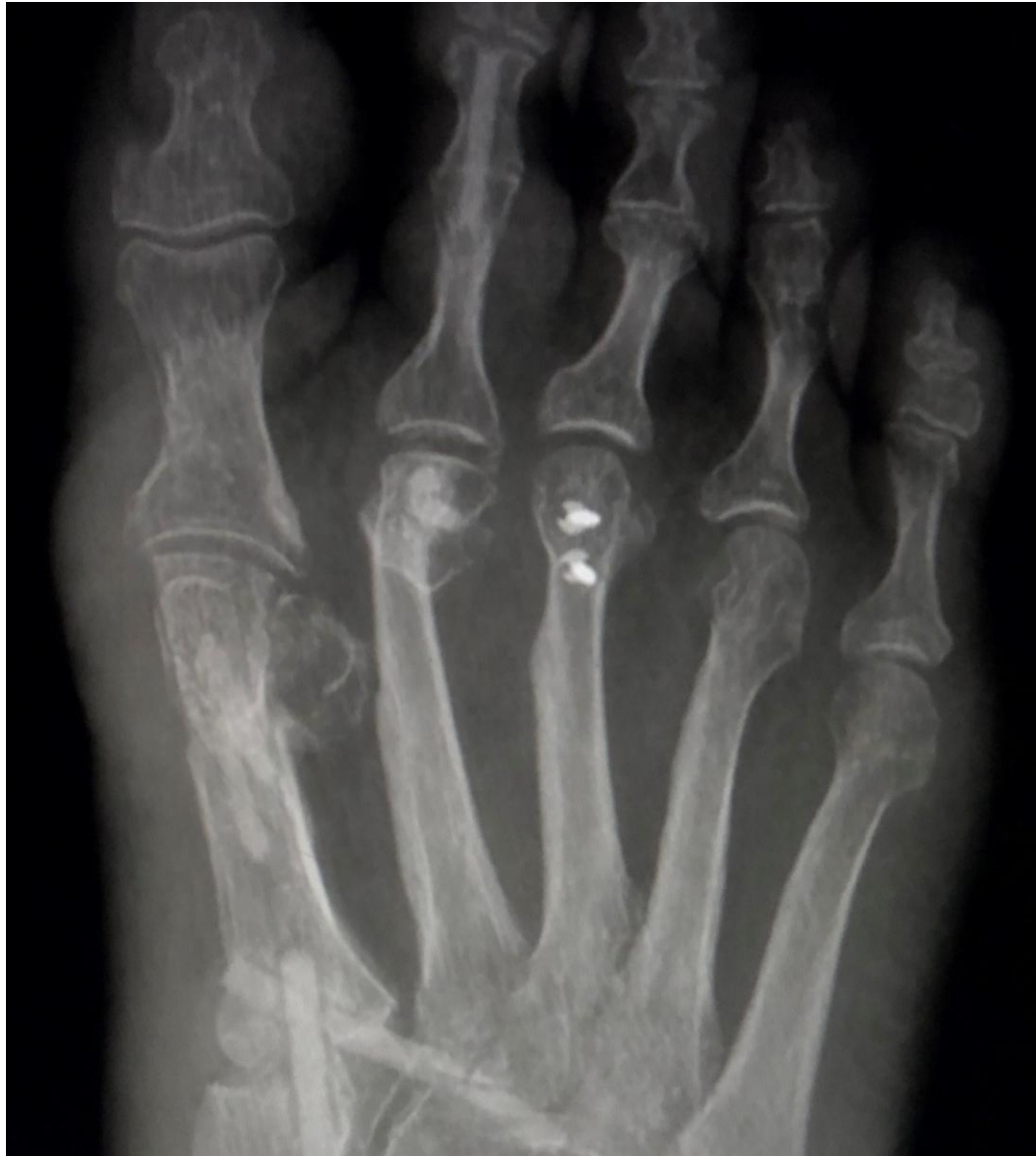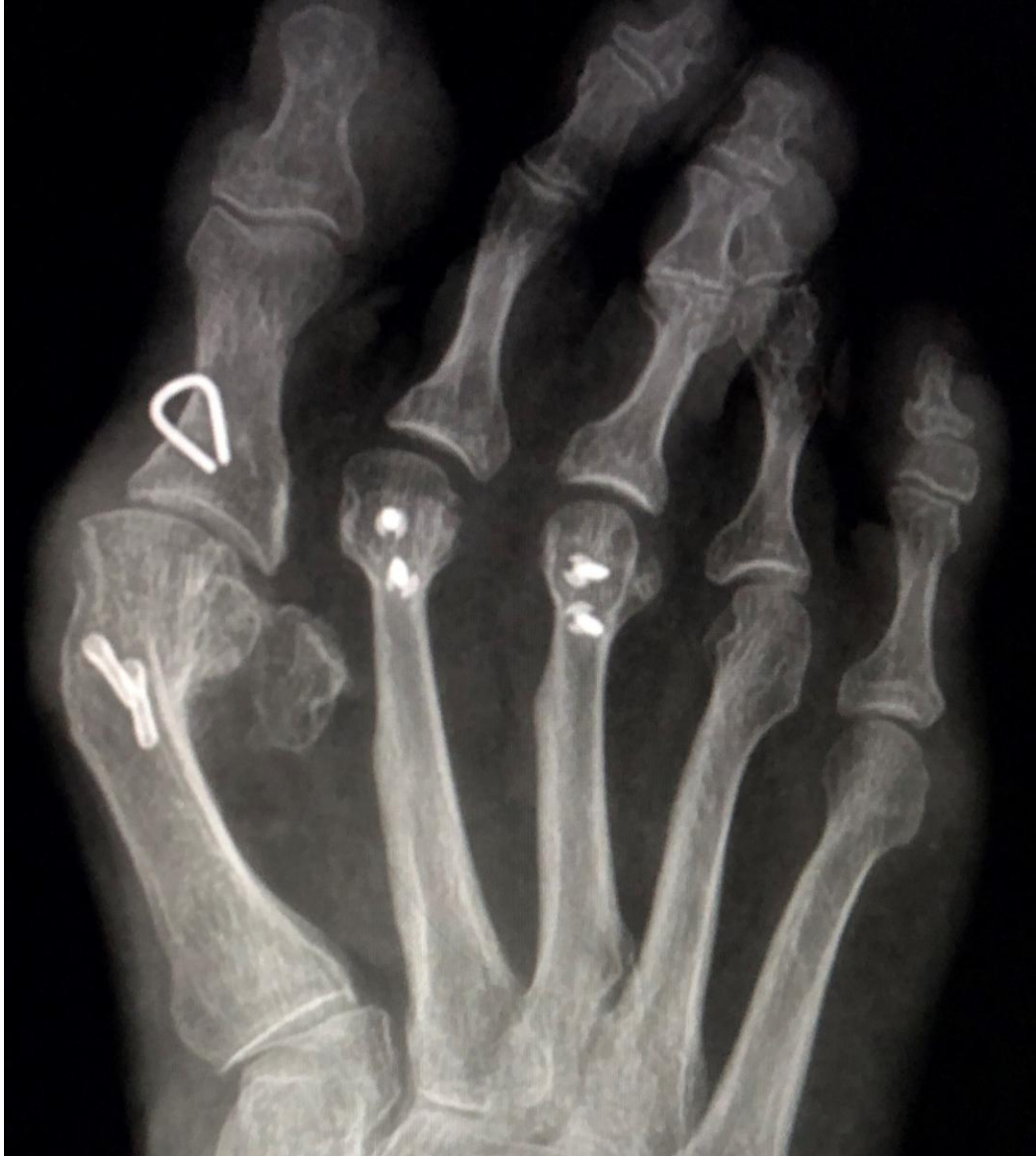# Failed Implant







**Need Less How  
and More Why....**



# **Bone Graft Indications/Uses:**

- **Assist in healing fractures (e.g stress and subchondral insufficiency), delayed unions or non-unions**
- **Assist in joint fusions**
- **Replace bone defects from trauma or tumor**
- **Act as a viable implant alternative for osteotomy and/or fracture fixation**

# **MAJOR CONSIDERATIONS:**

- **Thickness**
- **Elastic Modulus**
- **Decomposition Rate**



# Benefits:

- **Eliminates the risk of reaction to polymers or metals (e.g. osteolysis, metallosis)**
- **Eliminates the risk of pin-tract infection and implant migration**
- **Eliminates the need for a secondary hardware removal procedure**
- **Pin length is customized to each patients' individual needs**



# **Use of Allograft Bone Implants for Osseous Fixation**



# New Concept?

Reed TM: Allofix freeze-dried cortical bone pins as an alternative to synthetic absorbable polymeric pins: A preliminary study in short Z bunionectomies, *J Foot Ankle Surg* 38:14-23, 1999

Weintraub GM, Daulat R: The Evans Osteotomy: Technique and Fixation with Cortical Bone Pin, *J Foot and Ankle Surg*, Vol. 40, Number 1, January/February 2001

Ford TC, LM Maurer, KW Myick: Cortical bone pin fixation - A preliminary report on fixation of digital arthrodesis and distal chevron first metatarsal osteotomies, *J Foot Ankle Surg* 41:23-29, 2002

Kominsky SJ, Bermudez A, Bannerjee A: Using a Bone Allograft to Fixate Proximal Interphalangeal Joint Arthrodesis, *Foot & Ankle Specialist*, March 2013

# AlloMate® Bone Pin System

## WHAT IT IS...

**One solid piece of human bone allograft in a dowel configuration**

Processed from cortical ring from human femur and tibia

Cortical bone – high compression strength

Accredited Tissue Bank – Aseptic Processing + Sterile R

## WHAT IT ISN'T...

**a bio-engineered allograft**

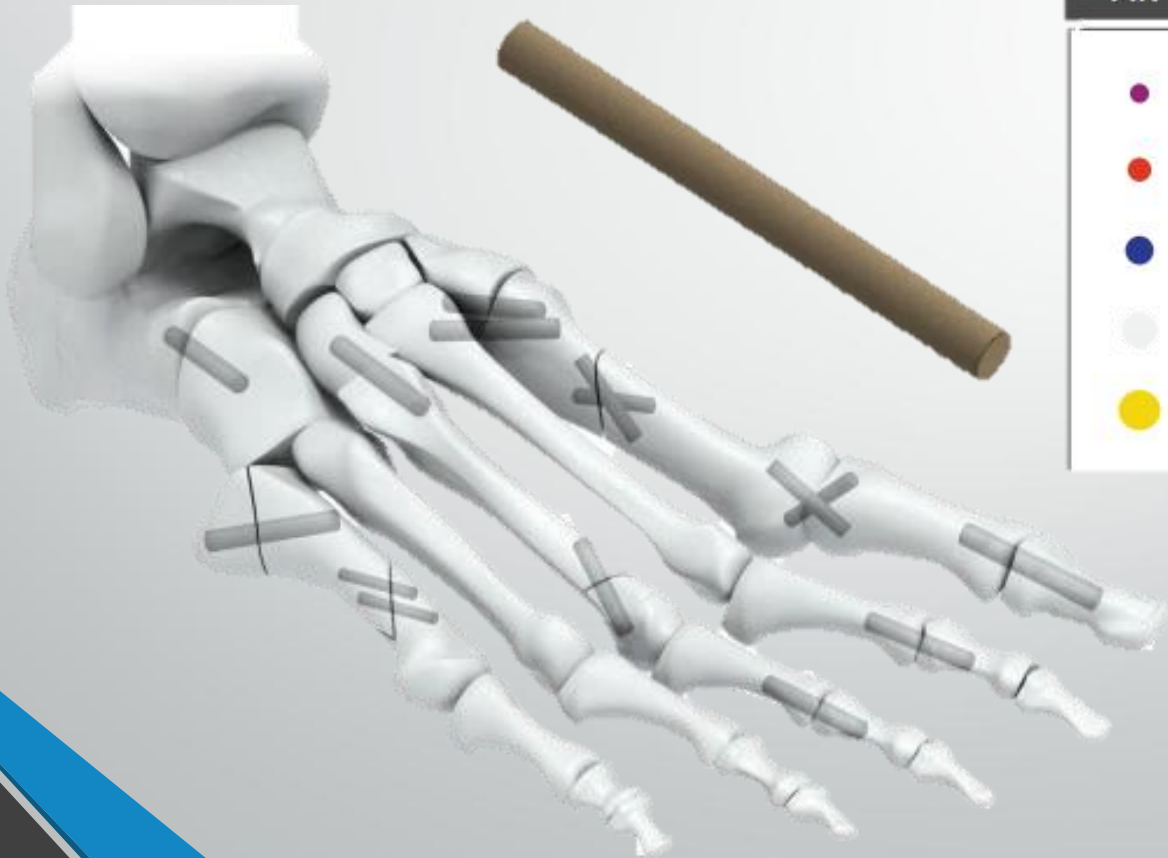
# **Rationale & Science: The AlloMate Bone Pin System**

***“The most logical way to closely mimic the physiological bone healing process while also stabilizing the osseous construct in a safe, reproducible and cost-effective manner.”***

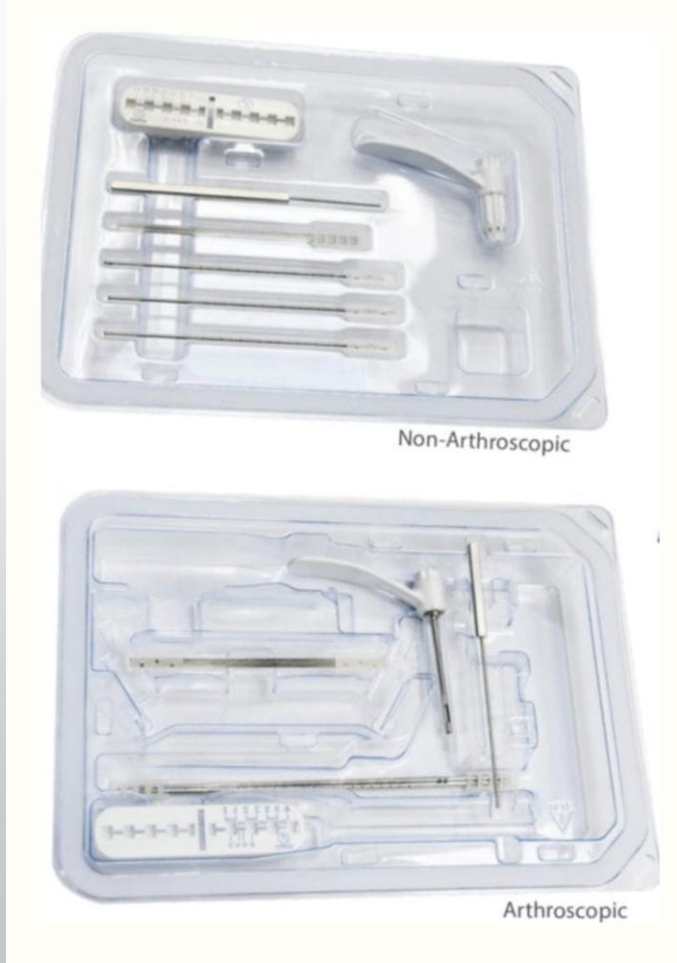- **Integrates via a well-known process of “creeping substitution”**
- **Alternative to metal, PEEK, and resorbable devices**
- **Can be easily identified on x-ray studies**

# AlloMate<sup>®</sup>

BONE PIN SYSTEM



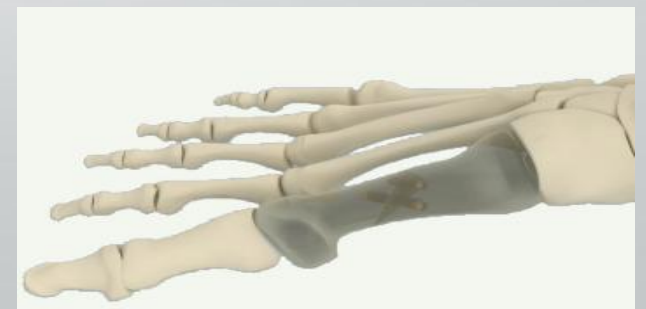
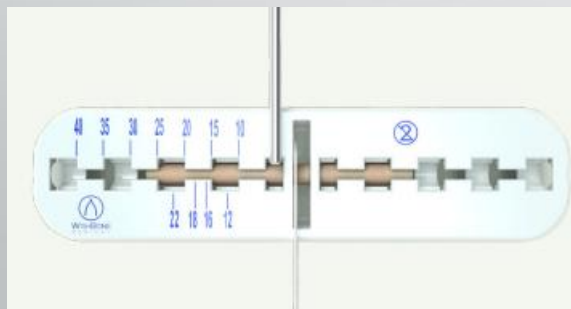
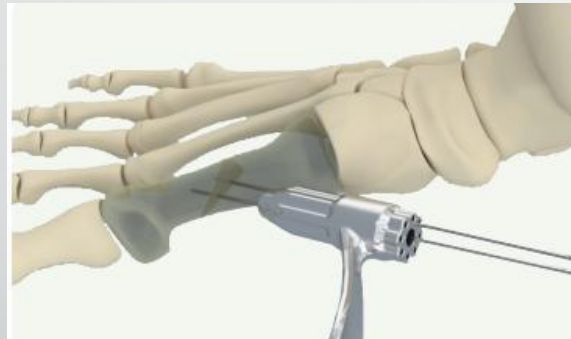
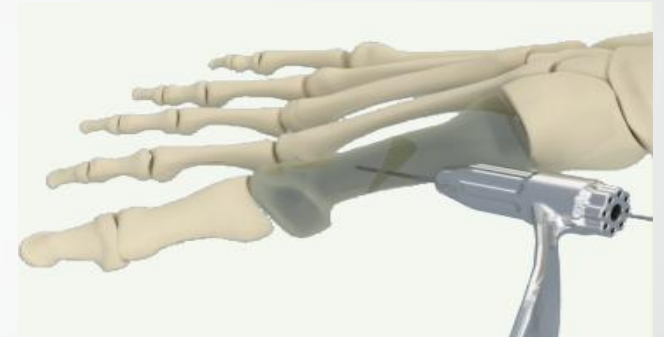
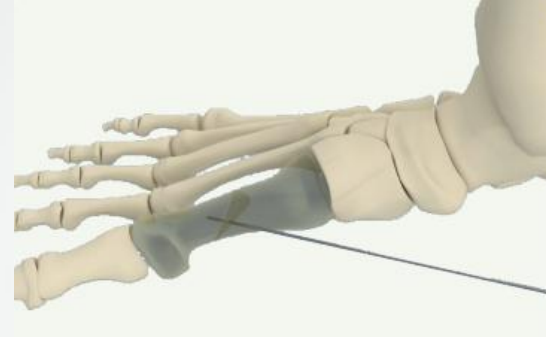
PIN DIAMETERS	
● 2.0mm	
● 2.5mm	
● 3.0mm	
● 3.5mm	
● 4.0mm	



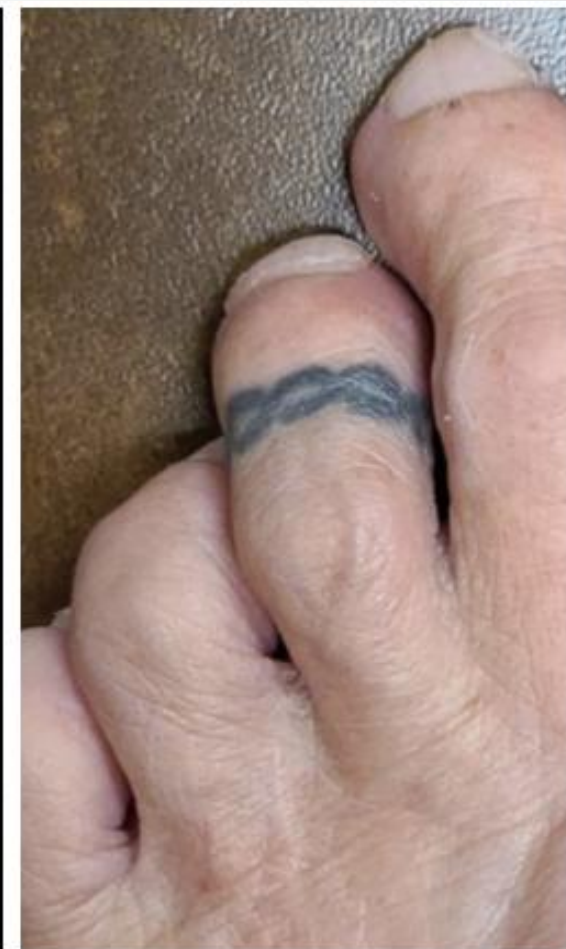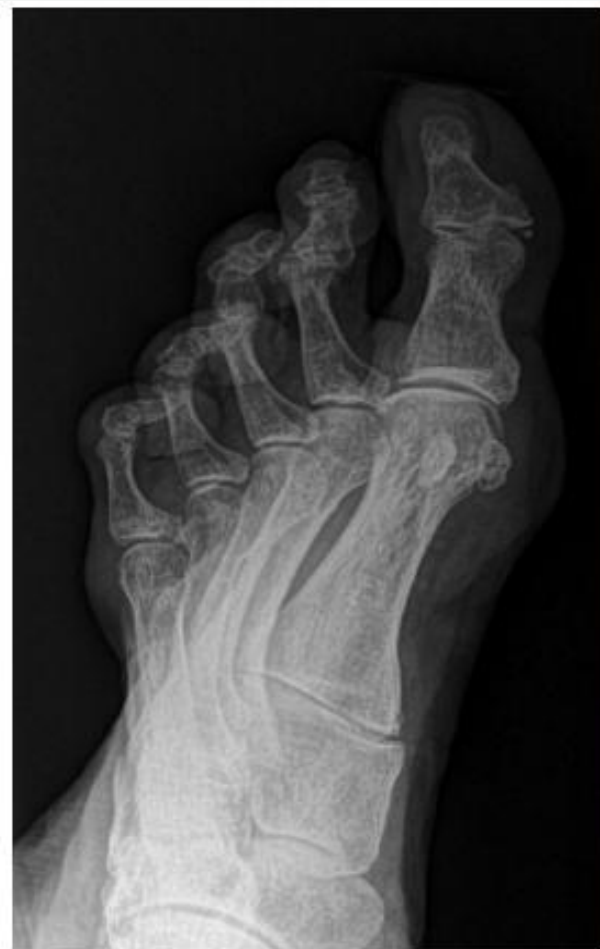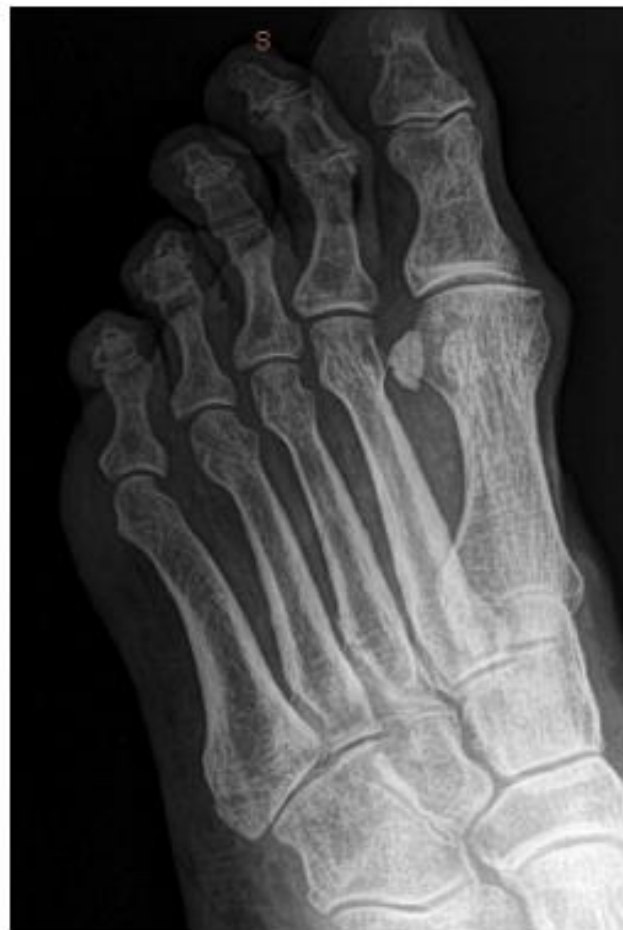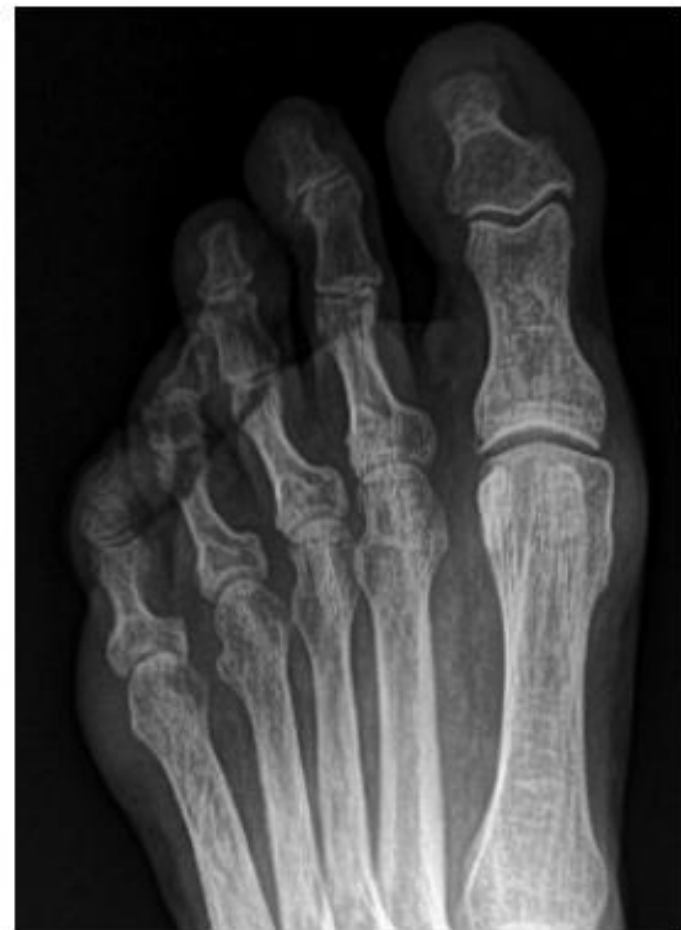# Indications for the Foot & Ankle

- **Digital deformities (hammertoe)**
- **Bunion**
  - **Austin**
  - **Akin**
  - **Lapidus**
  - **Tailor's Bunionectionomy**
- **Weil Osteotomy**
- **Trauma**
  - **5<sup>th</sup> Metatarsal Fractures,**
  - **Medial Malleolar Fractures**
  - **Calcaneal Fractures**
  - **Loose OCD Lesions**
- **Freiberg's Disease**
- **Pediatric Flatfoot Correction**
  - **Medial Calcaneal Slide Osteotomy**
  - **Evans procedure**

# Surgical Technique Overview

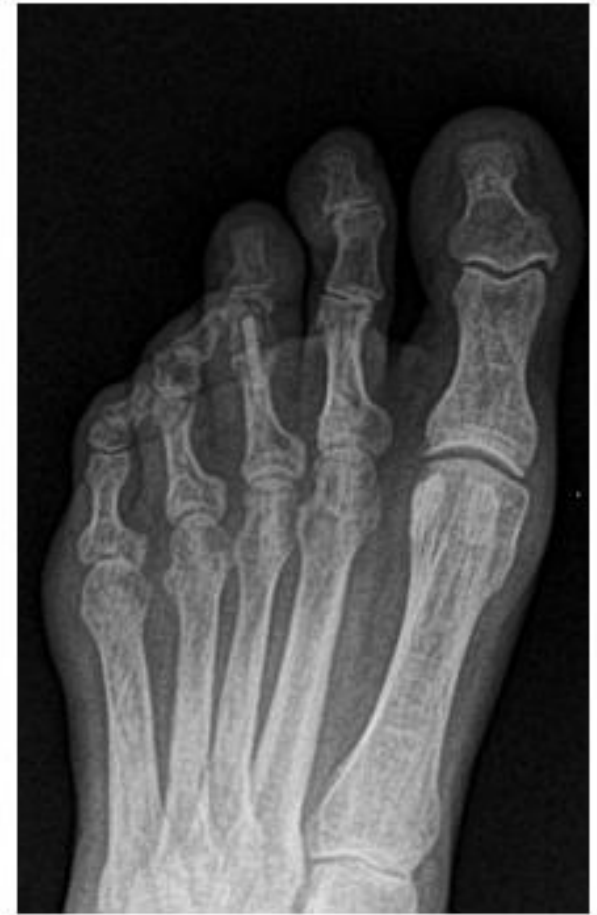
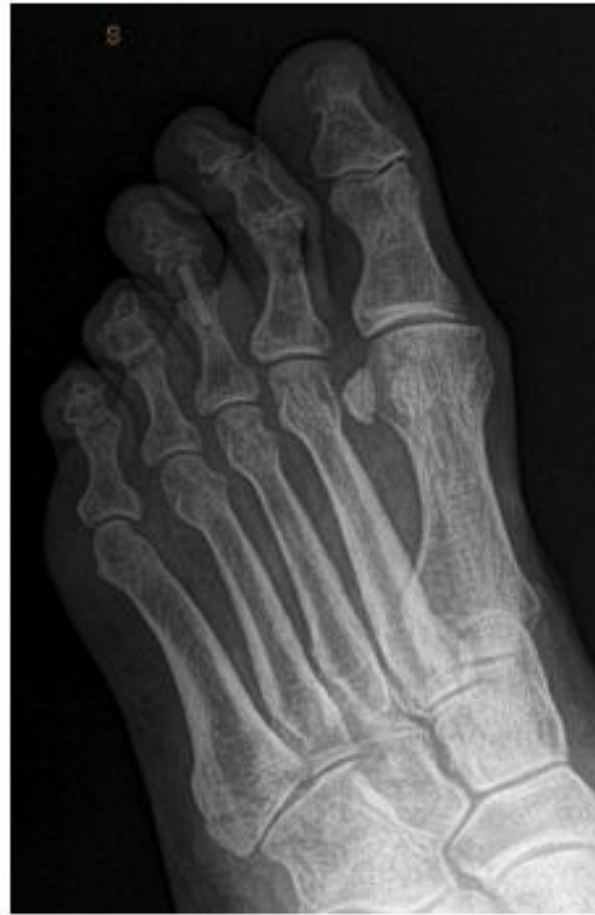
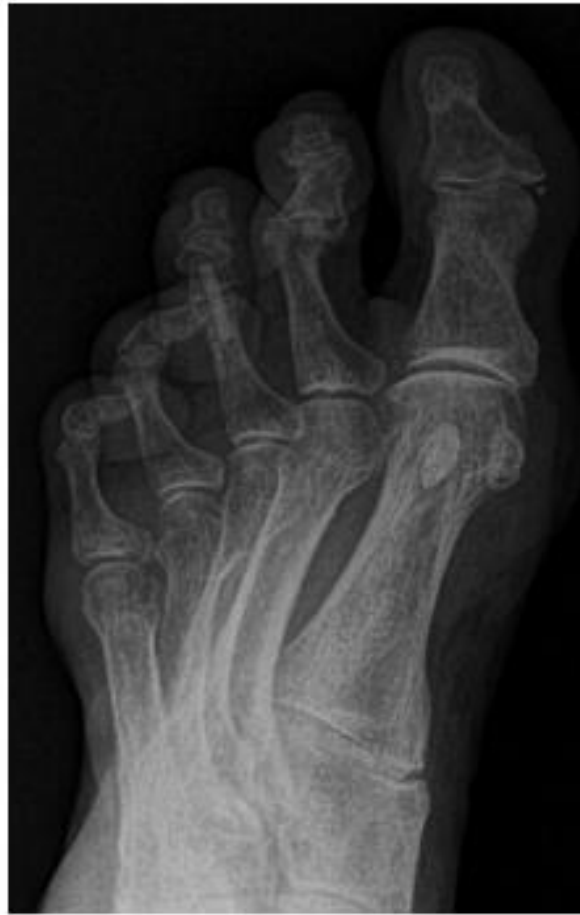# Hammertoe Repair



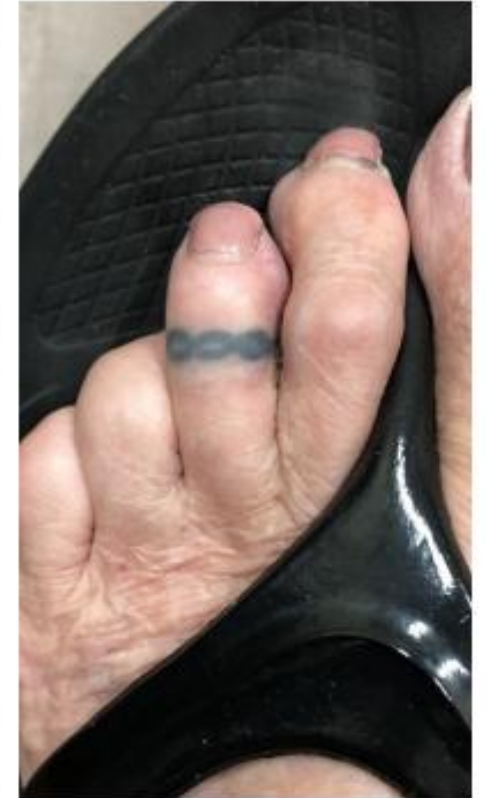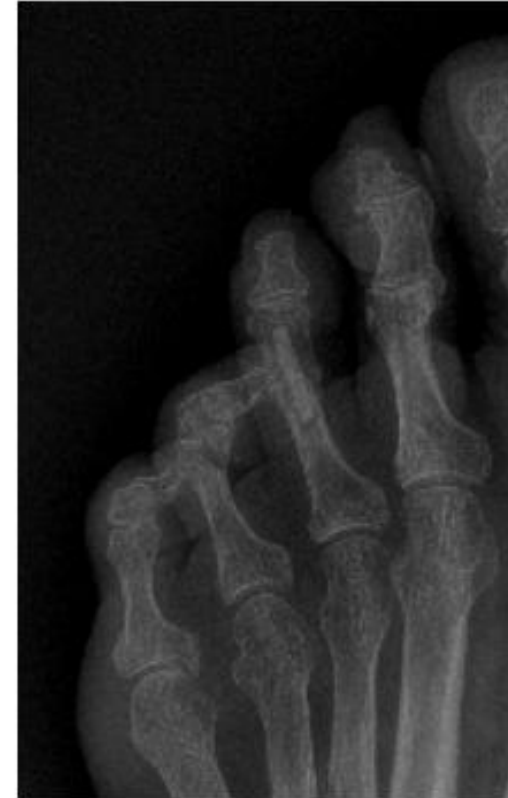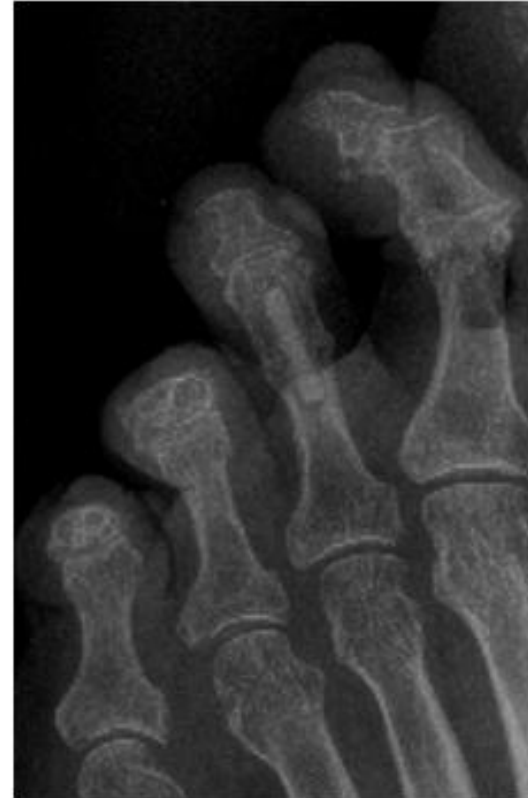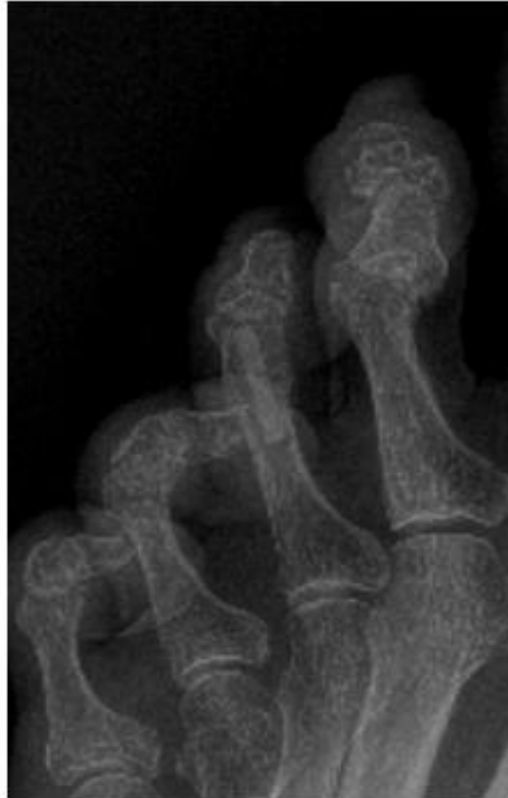# Hammertoe Repair

1 week post-operative

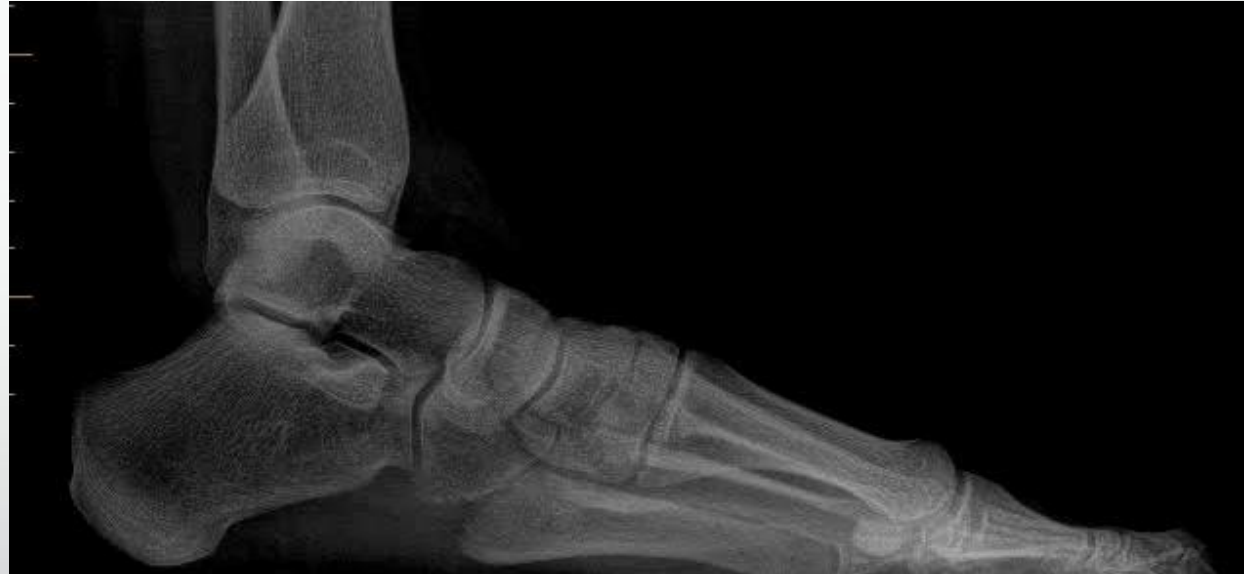
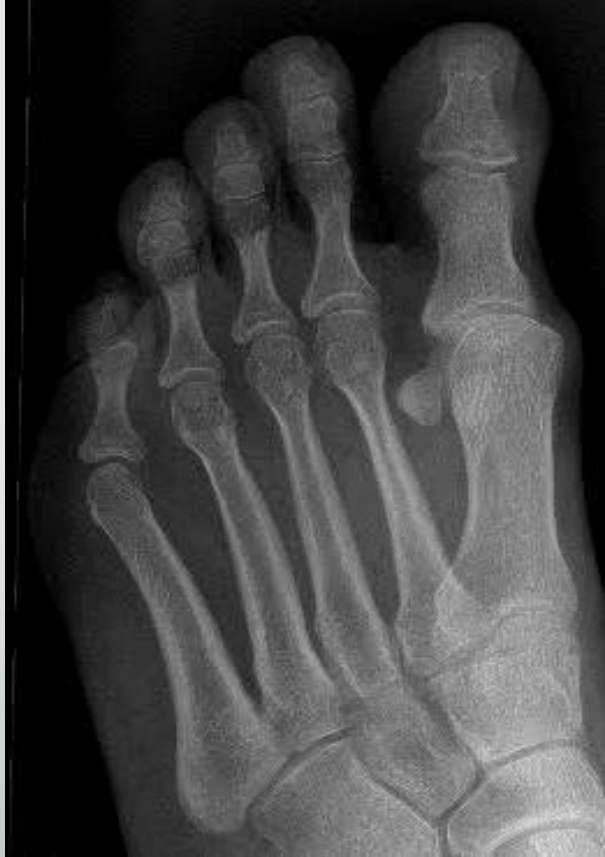
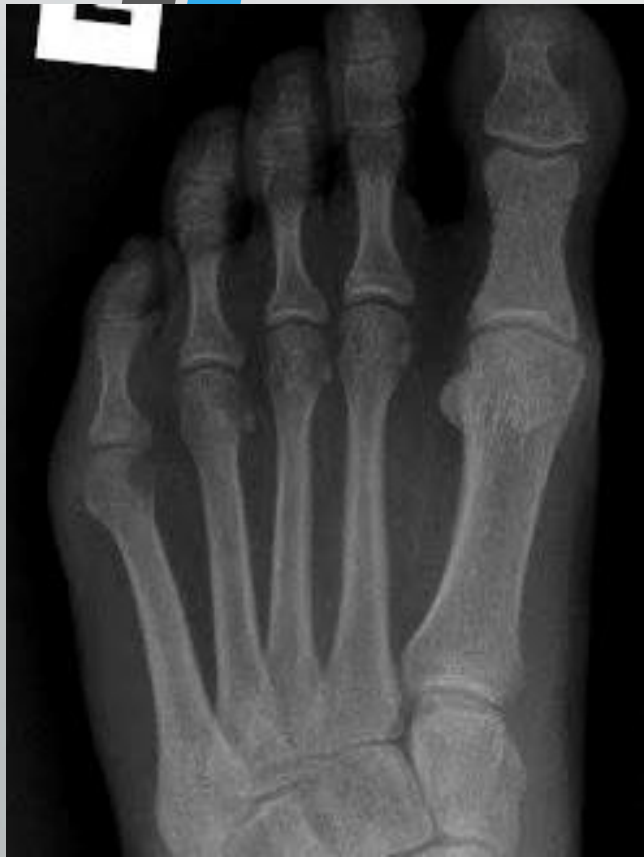# Hammertoe Repair

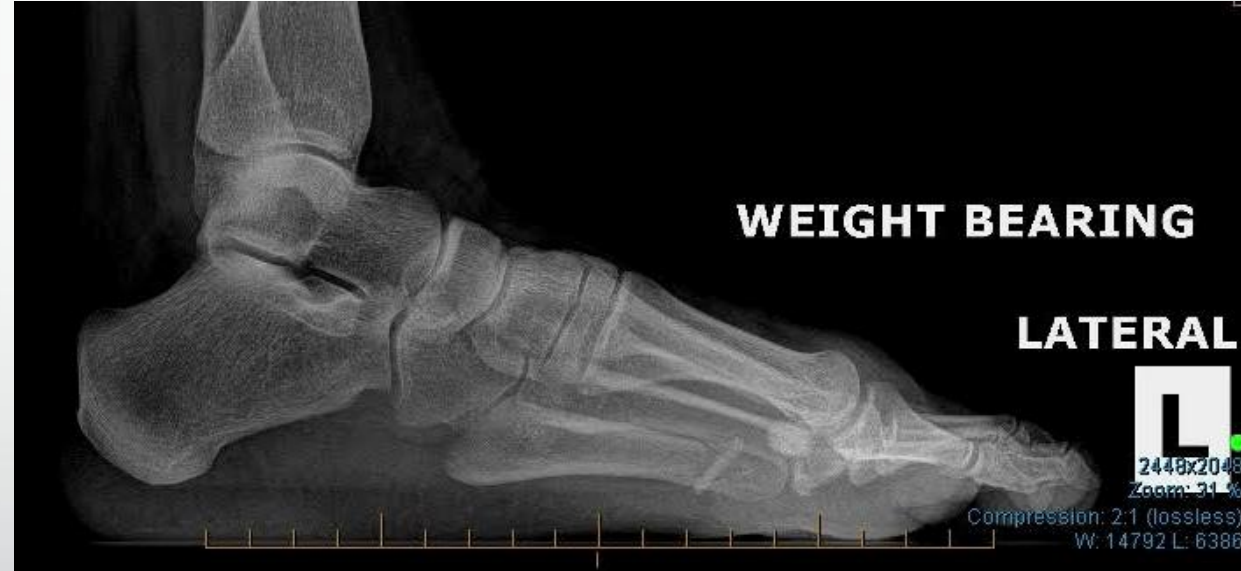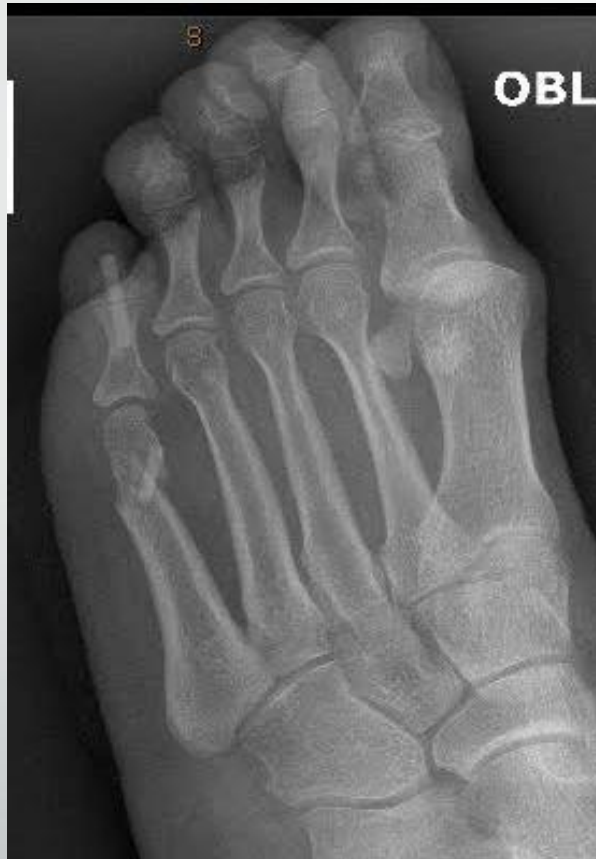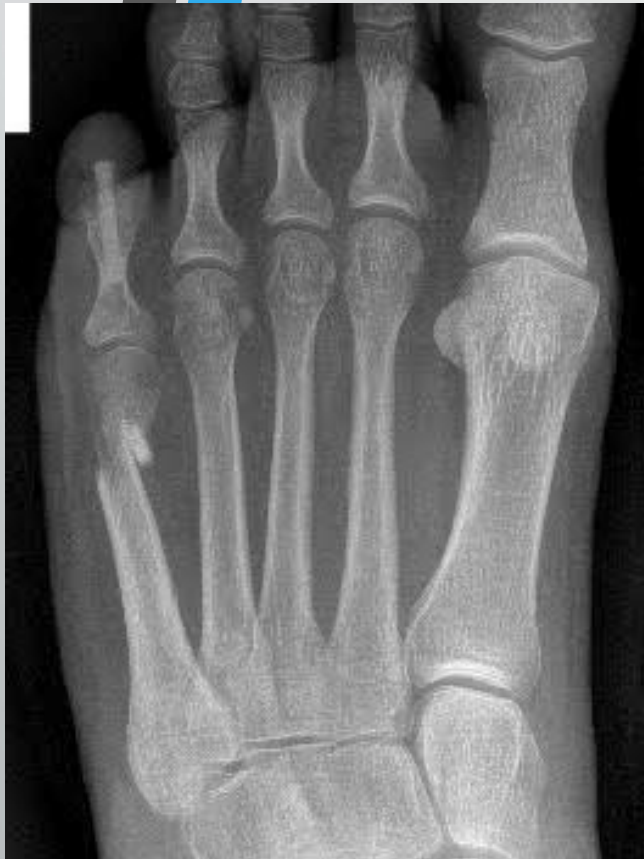13 months post-operative



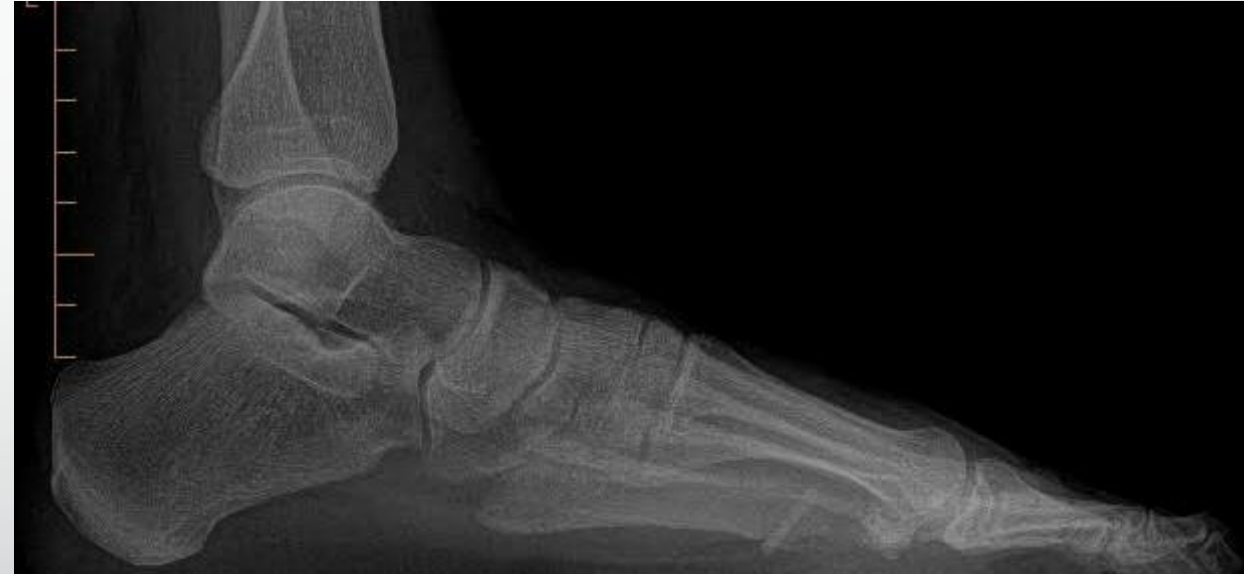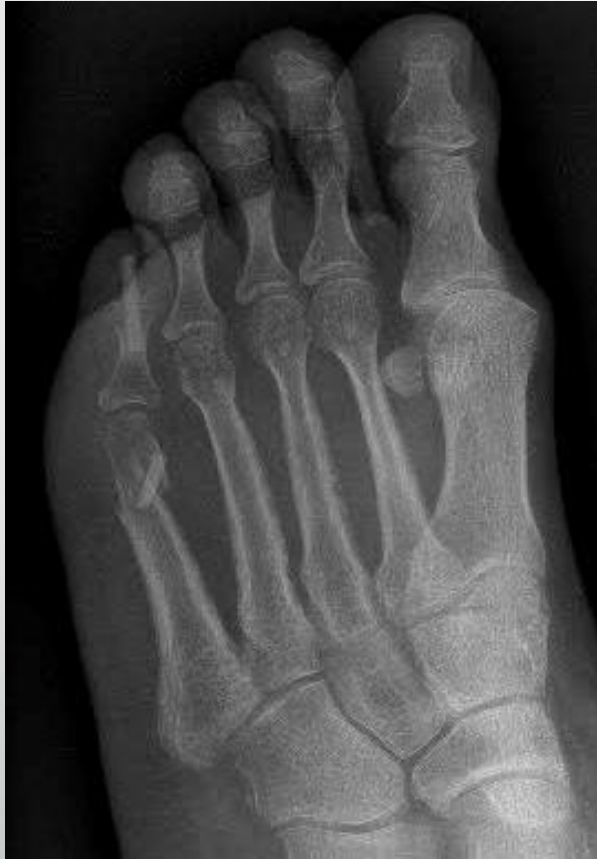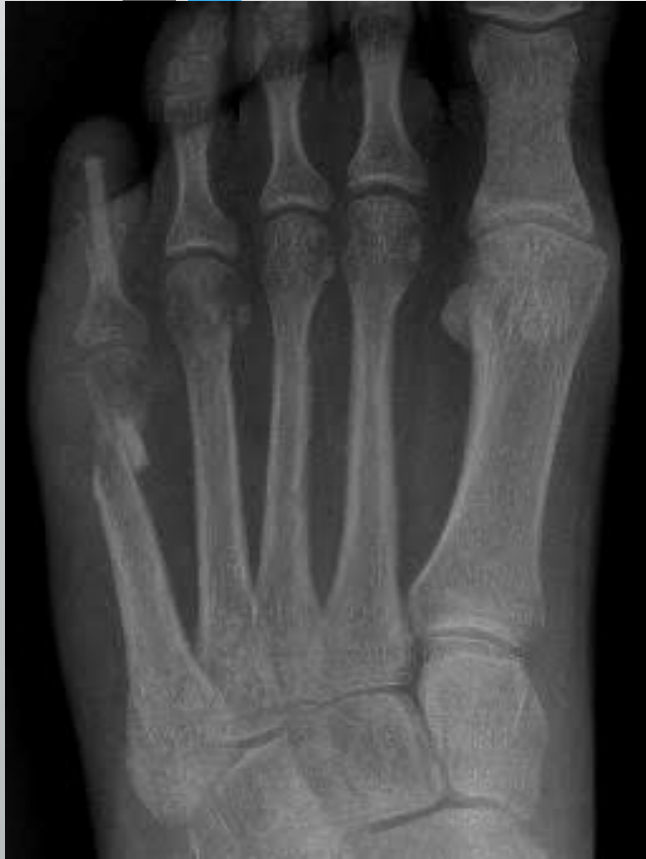# Tailor's Bunion with Fifth Digit Hammertoe



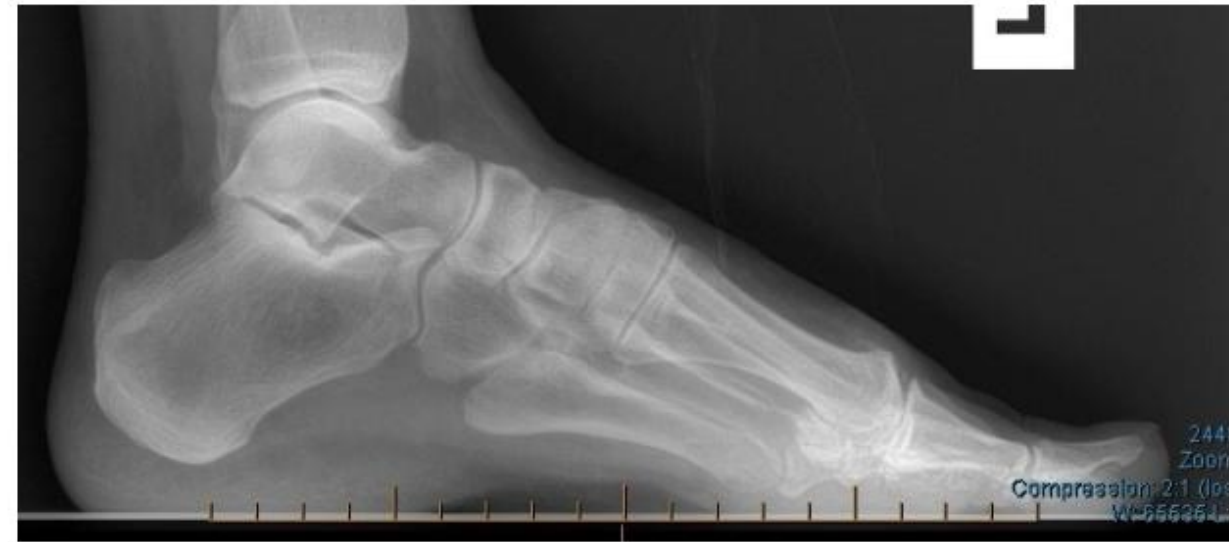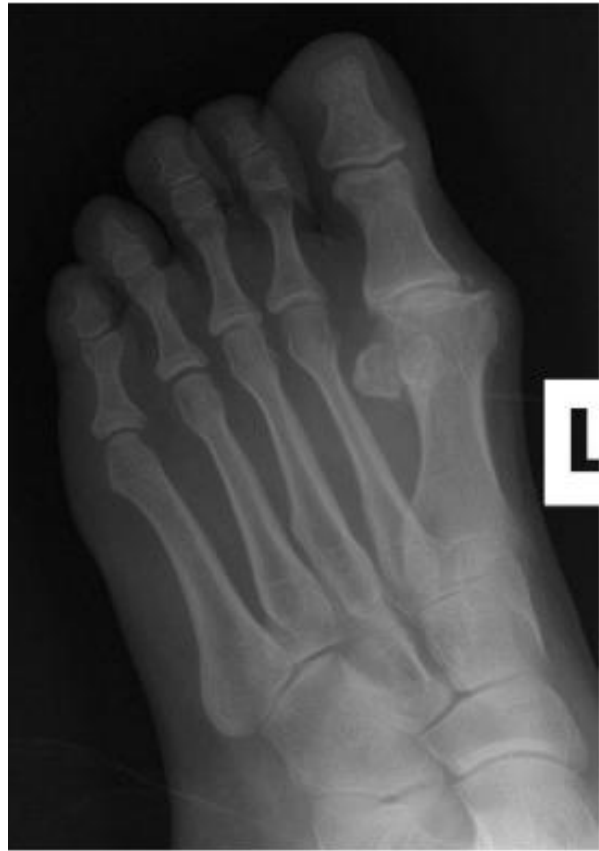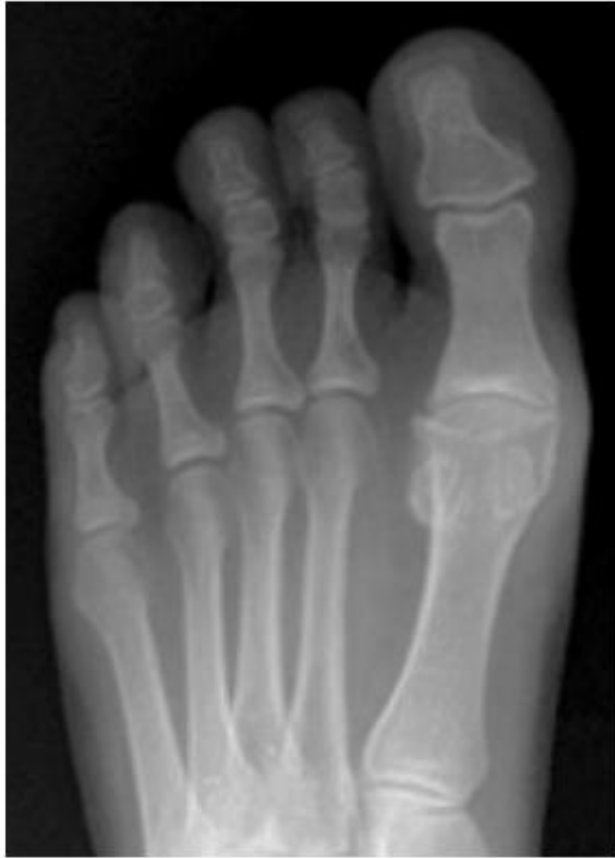# Tailor's Bunionectomy with Fifth Digit Hammertoe Repair – One Week P.O.



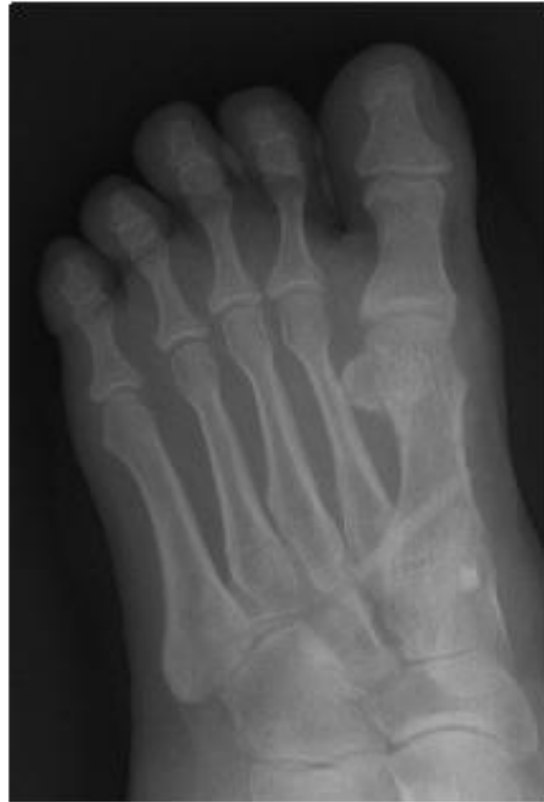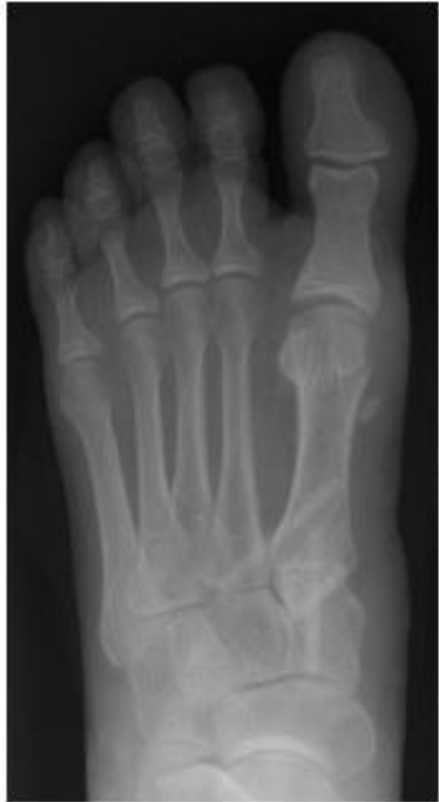# Tailor's Bunionectionomy with Fifth Digit Hammertoe Repair – Six Week P.O.



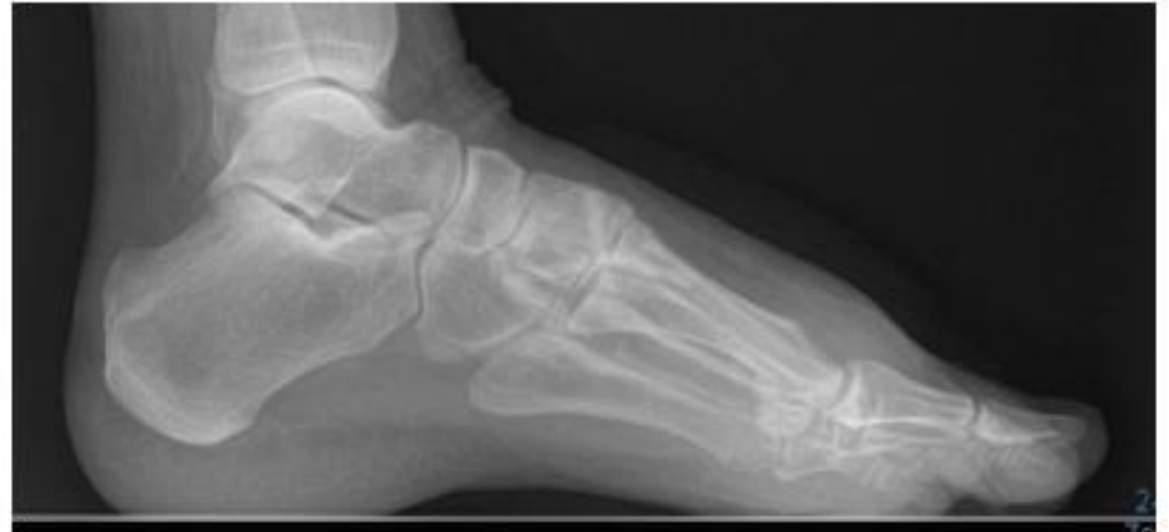# Left Foot Bunion and an Elevated/Long First Metatarsal with Hallux Limitus



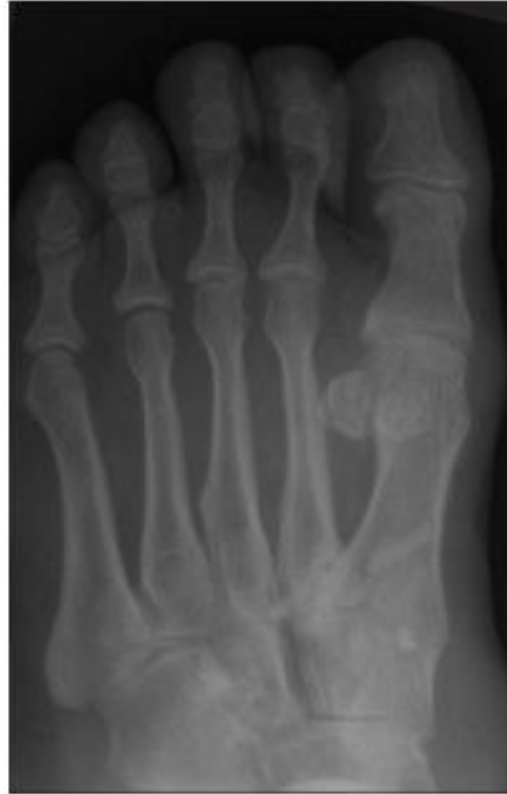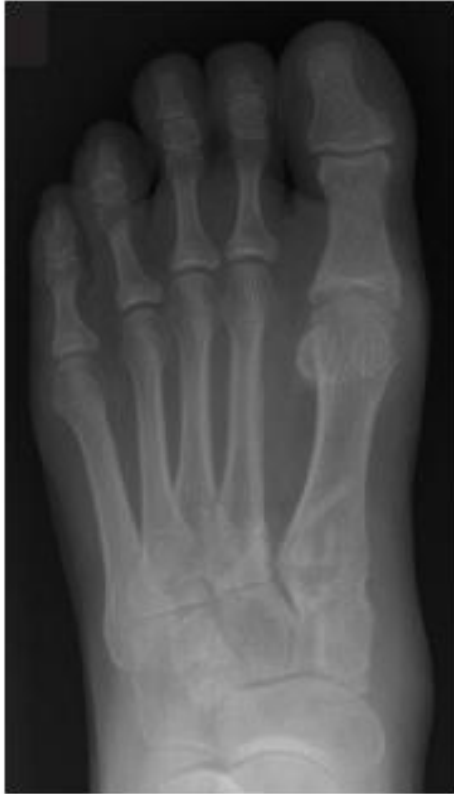# Left Foot Bunion and an Elevated/Long First Metatarsal with Hallux Limitus



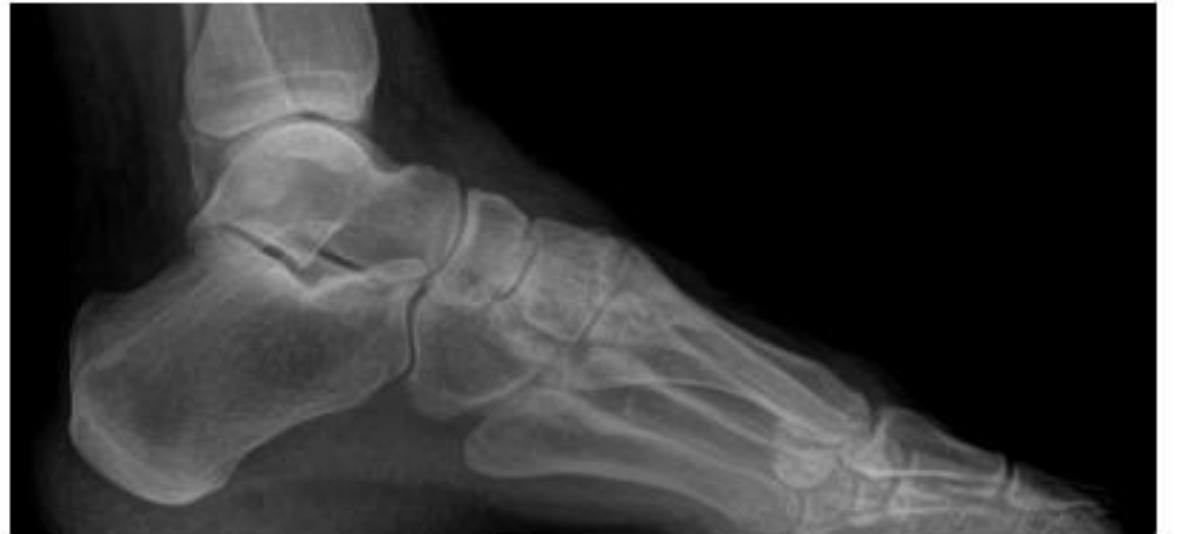1 WEEK POST-OPERATIVE



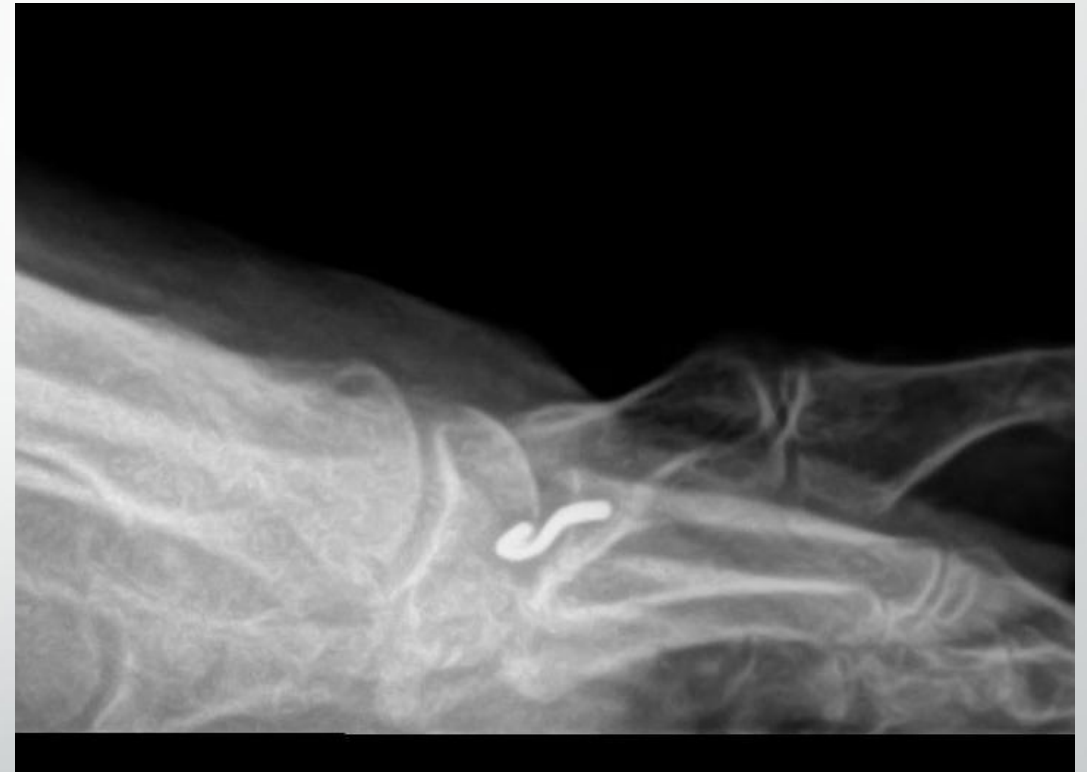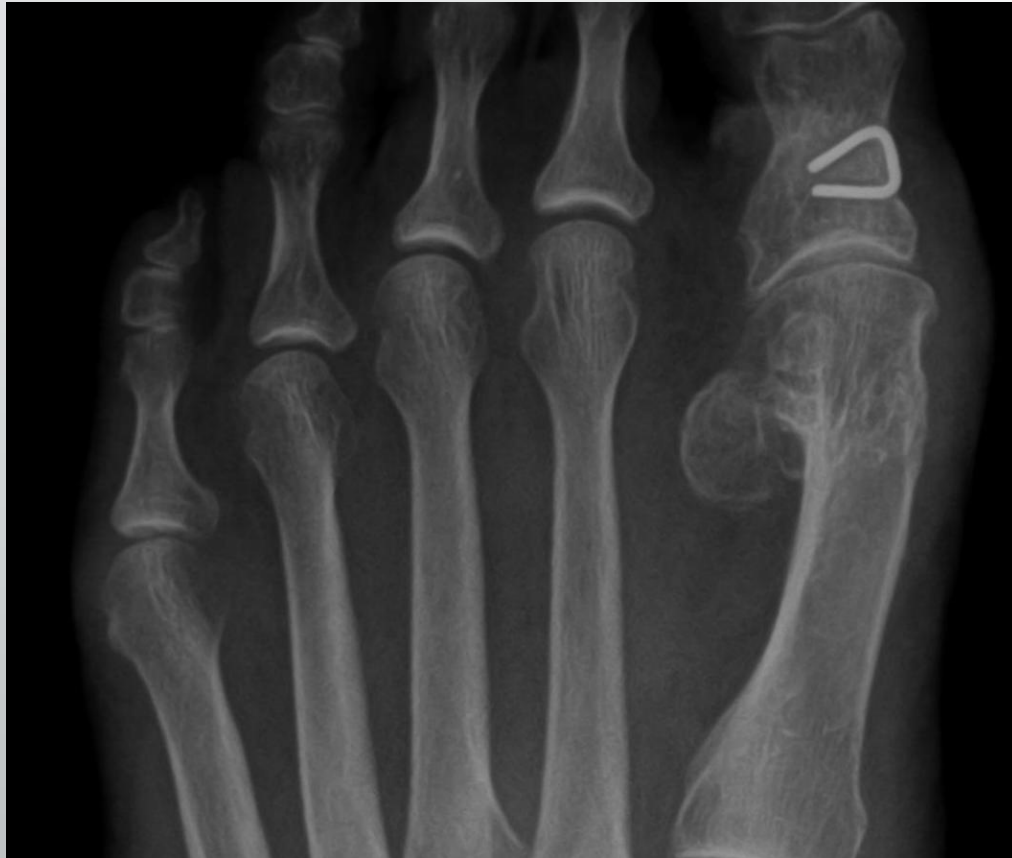# Left Foot Bunion and an Elevated/Long First Metatarsal with Hallux Limitus



7.5 MONTHS POST-OPERATIVE

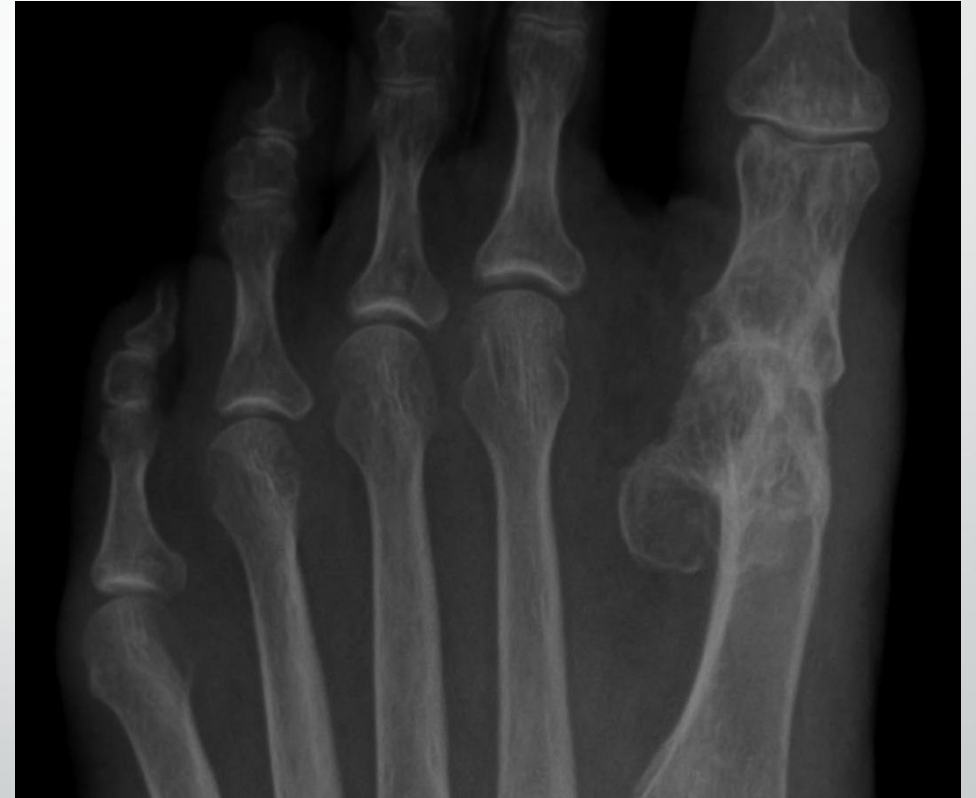
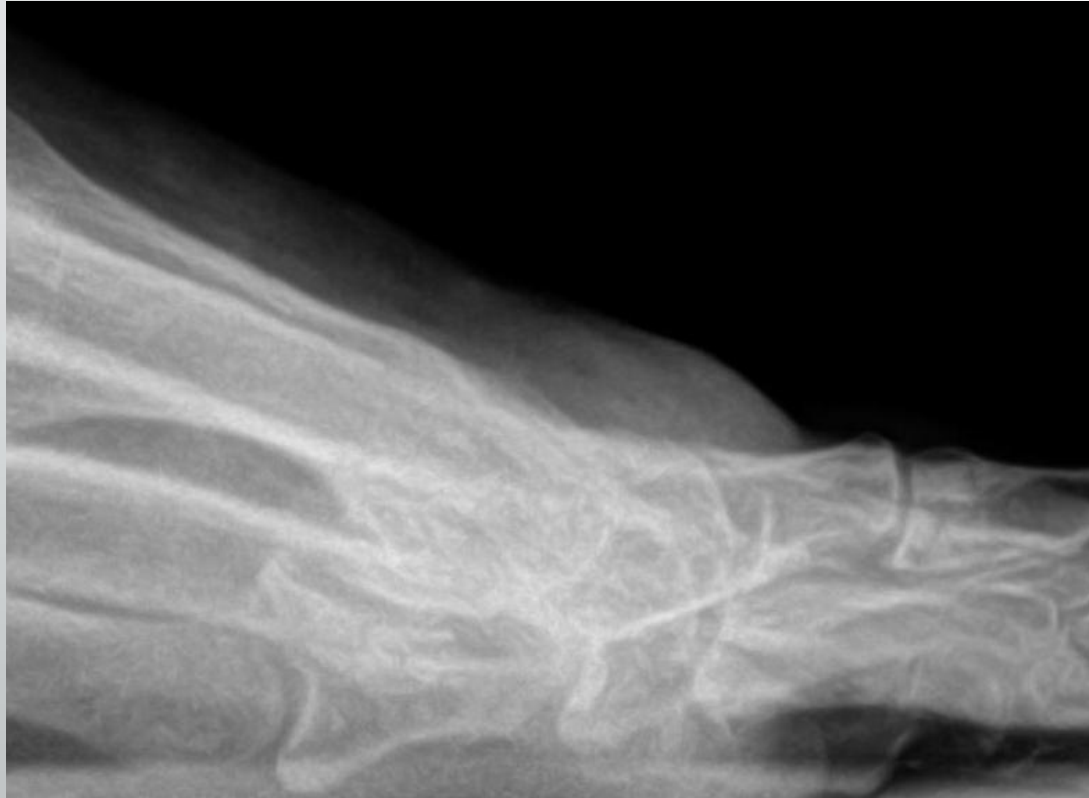
# First MPJ Fusion for Failed Bunionelectomy

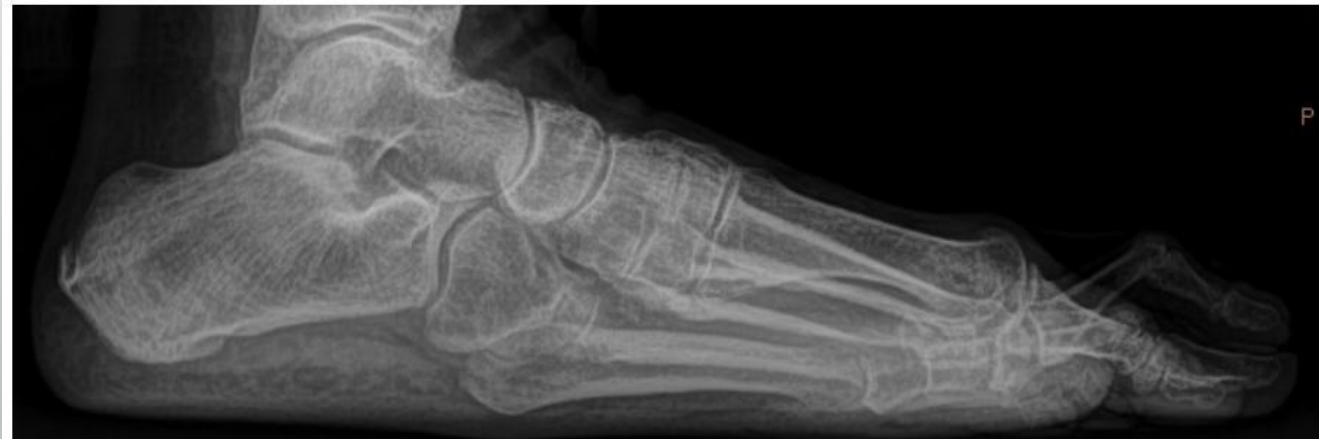
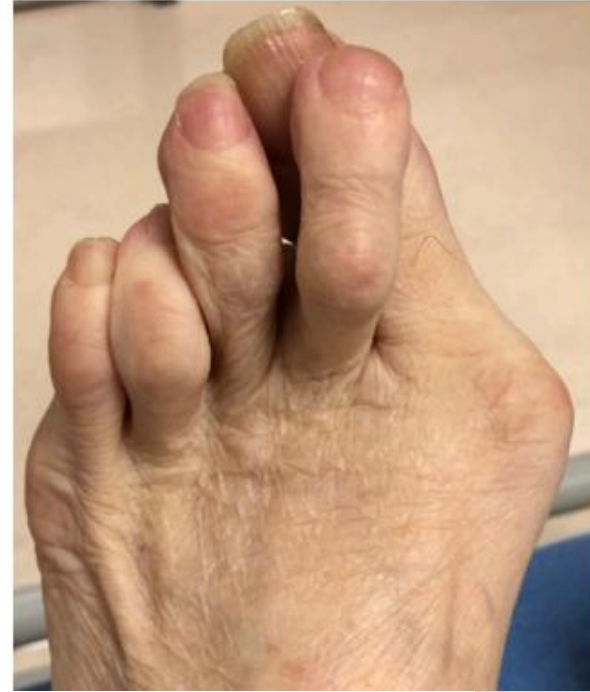
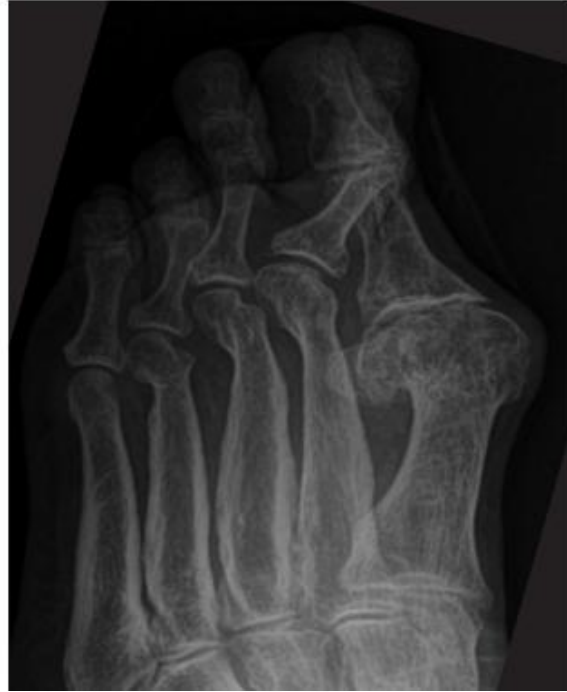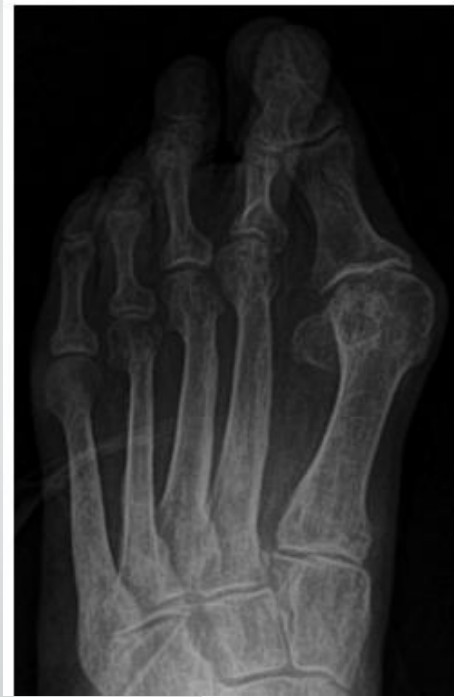# First MPJ Fusion for Failed Bunionelectomy

5 Months Post-Op

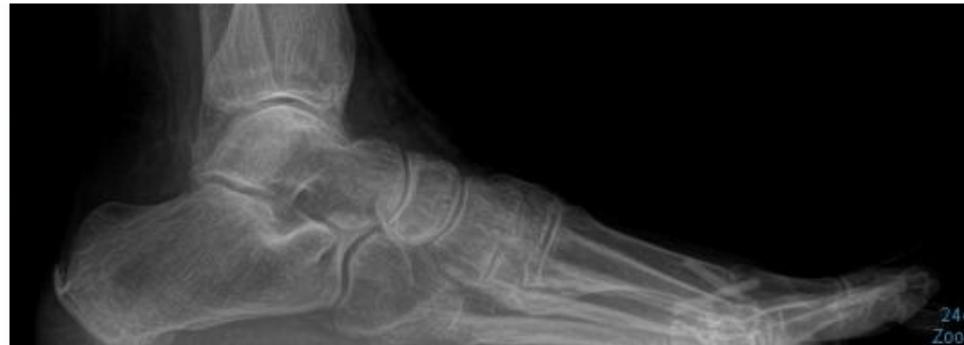
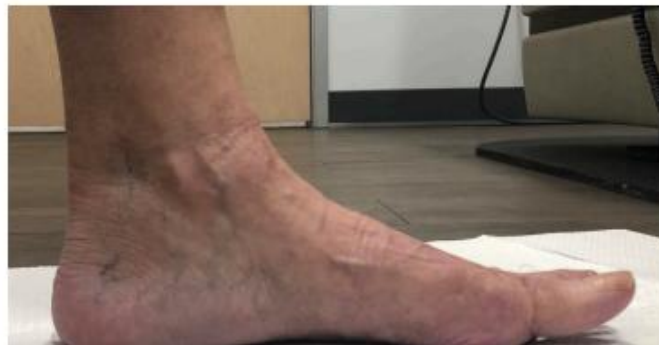
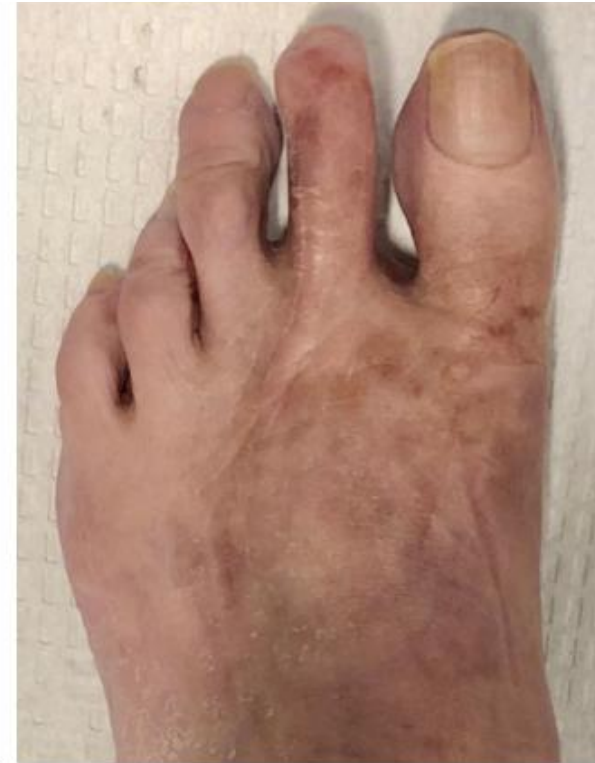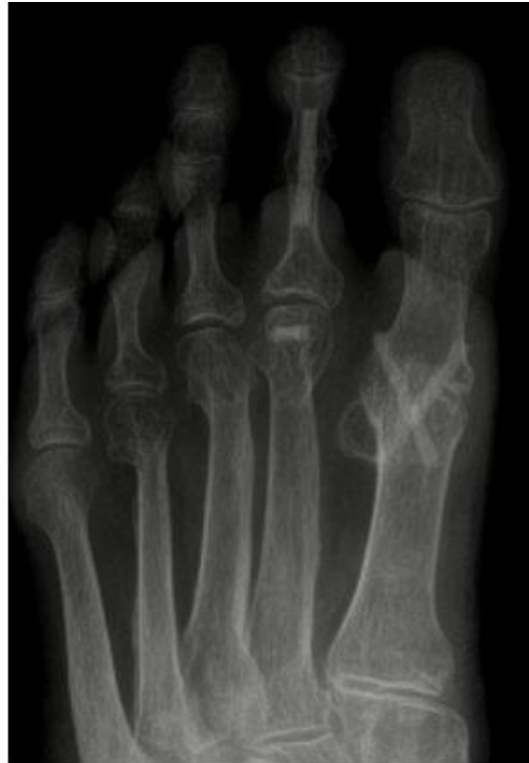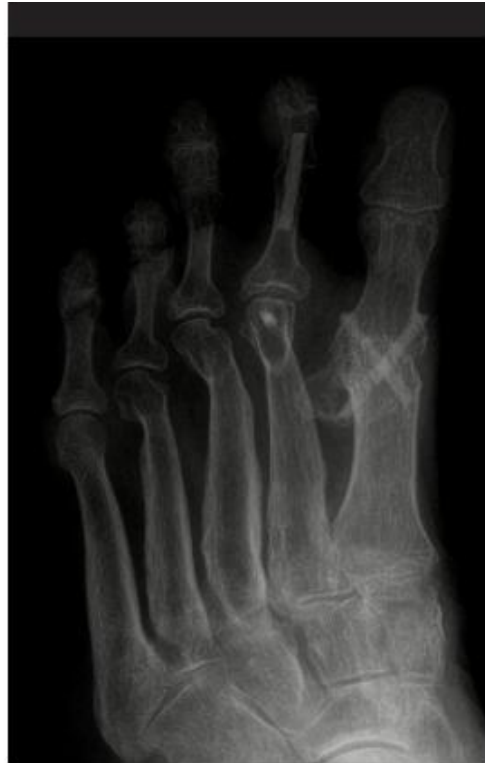# Left Foot Bunion and Non-Reducible Cross-Over Second Digit

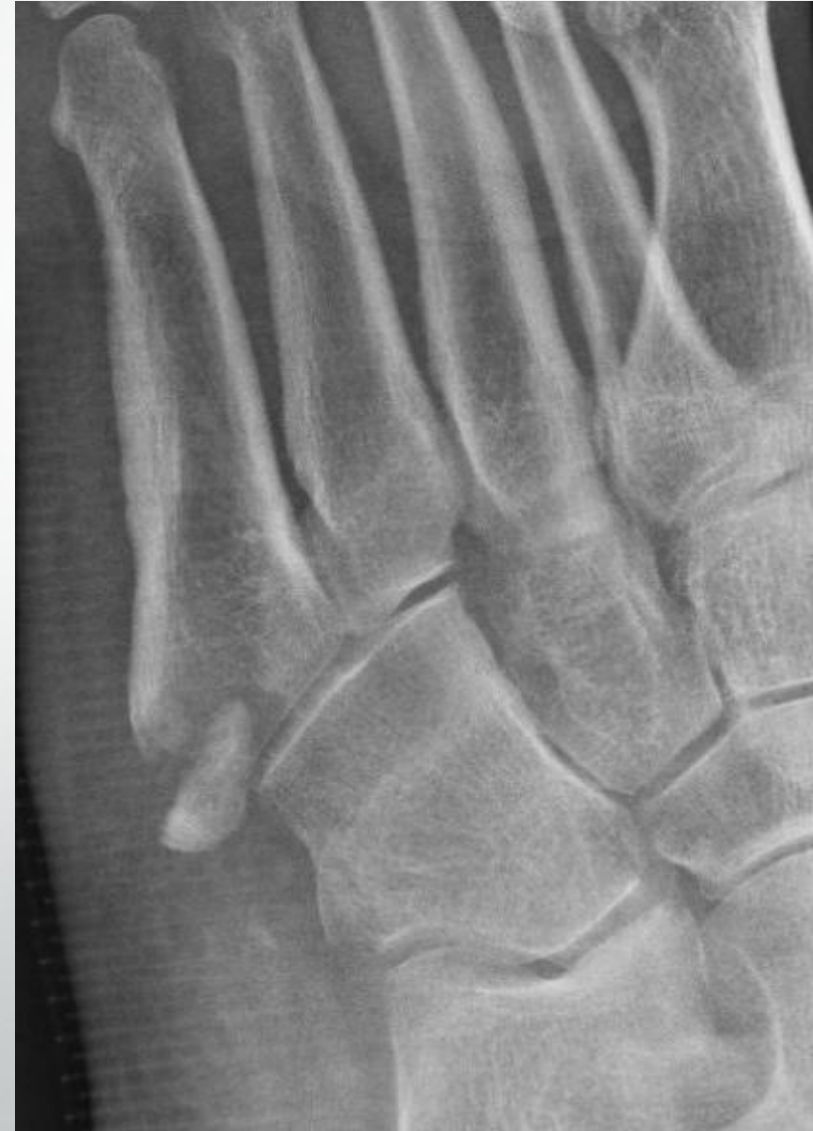
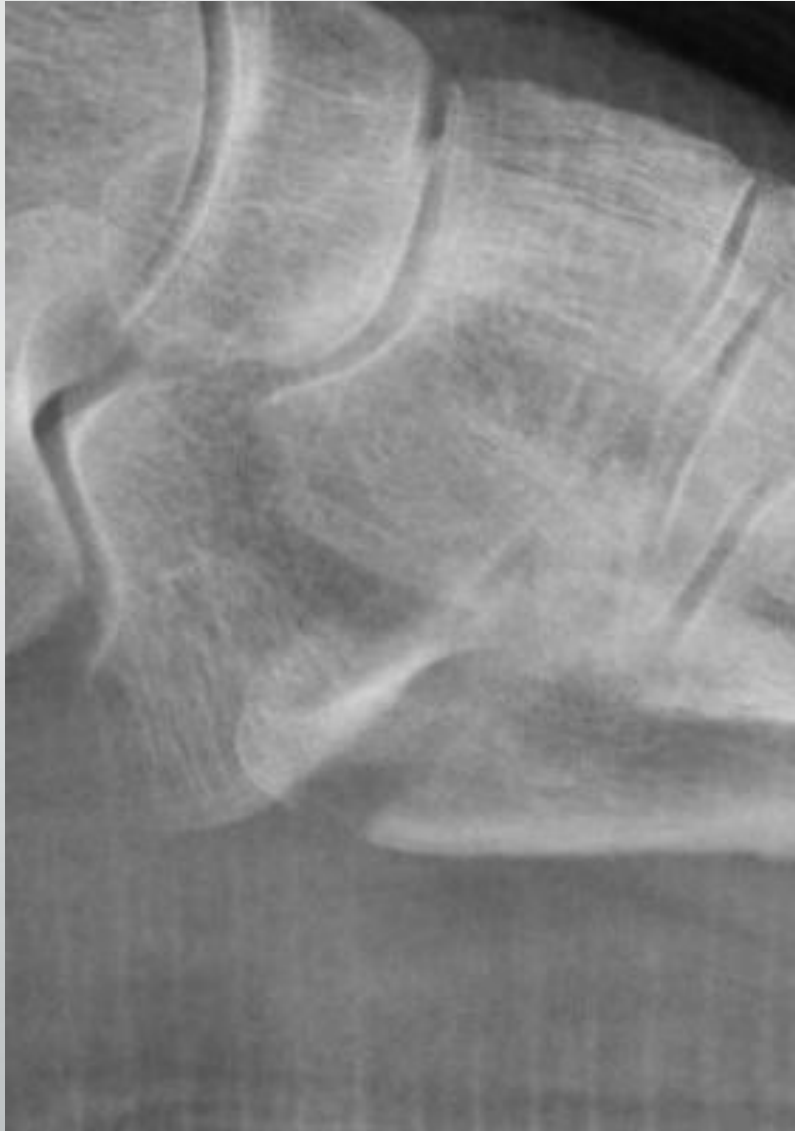
# Left Foot Bunion and Non-Reducible Cross-Over Second Digit

6 MONTH POST-OPERATIVE

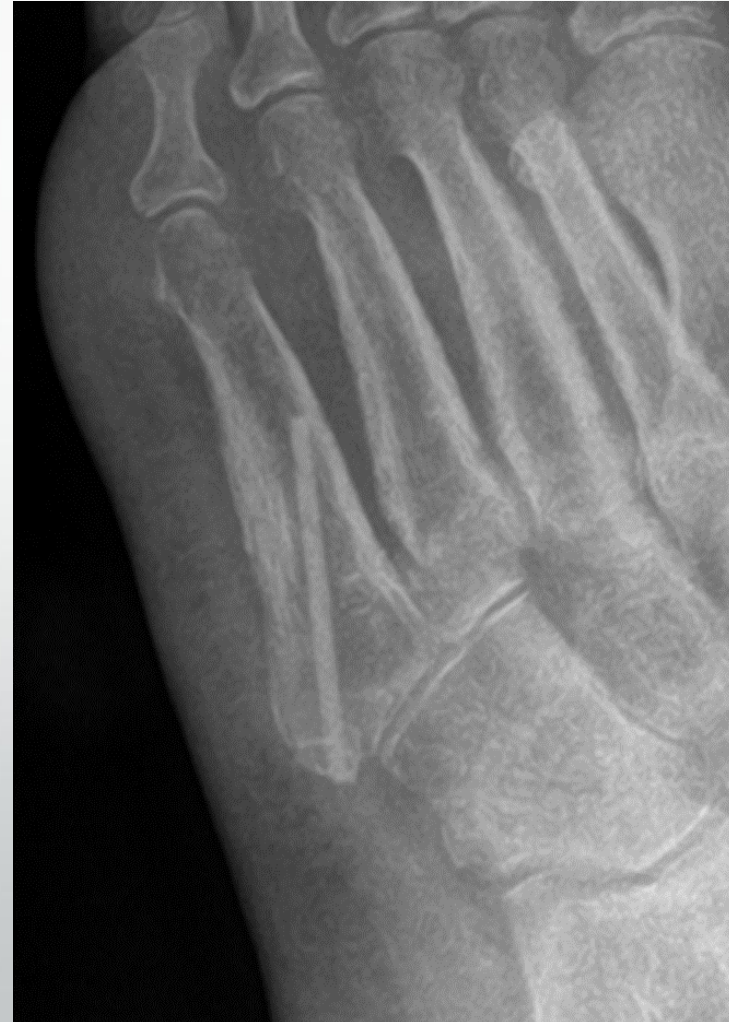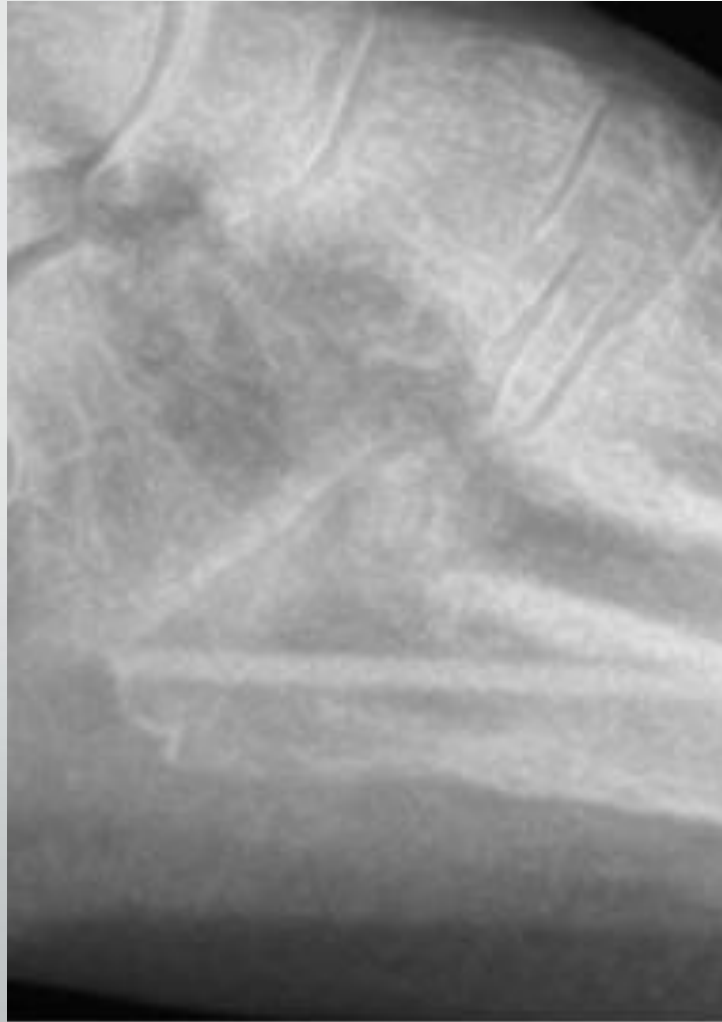


# Avulsion Fracture 5<sup>th</sup> Metatarsal

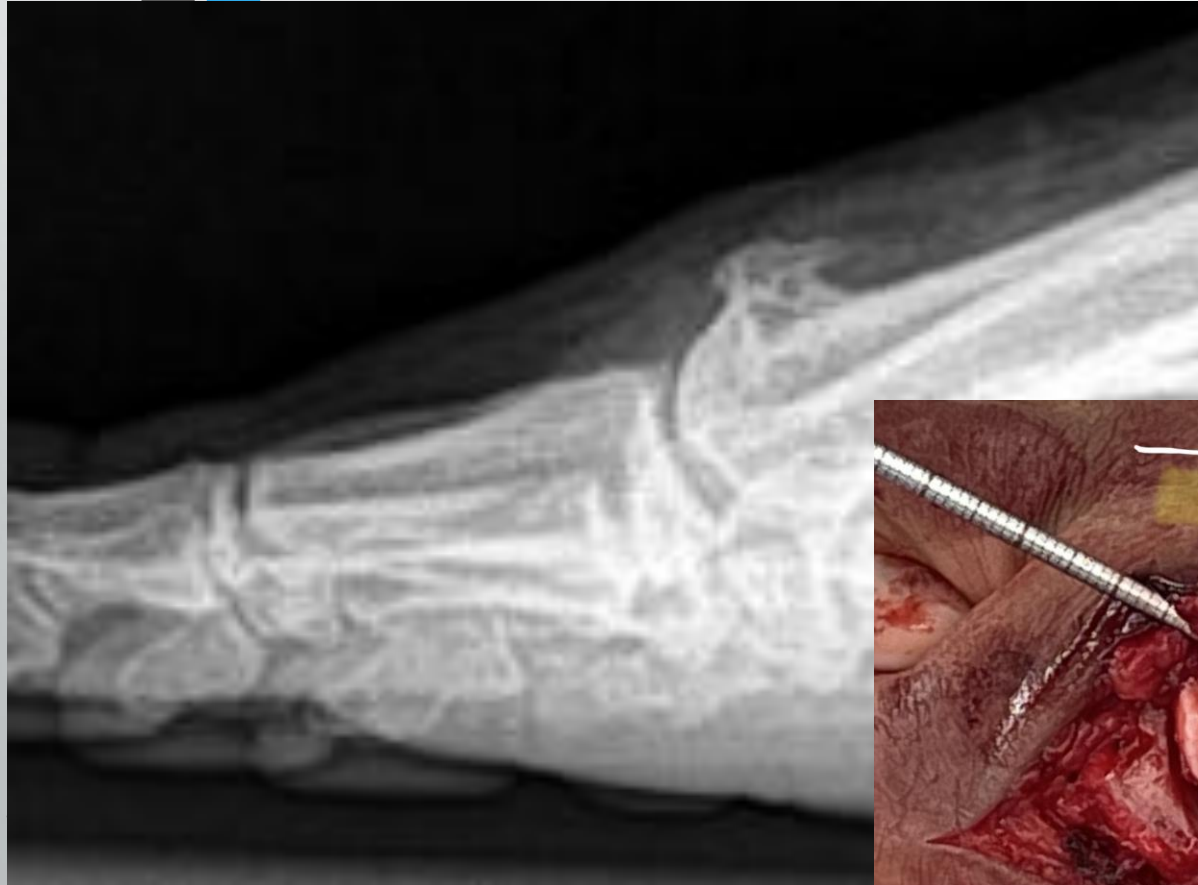


# Avulsion Fracture 5<sup>th</sup> Metatarsal

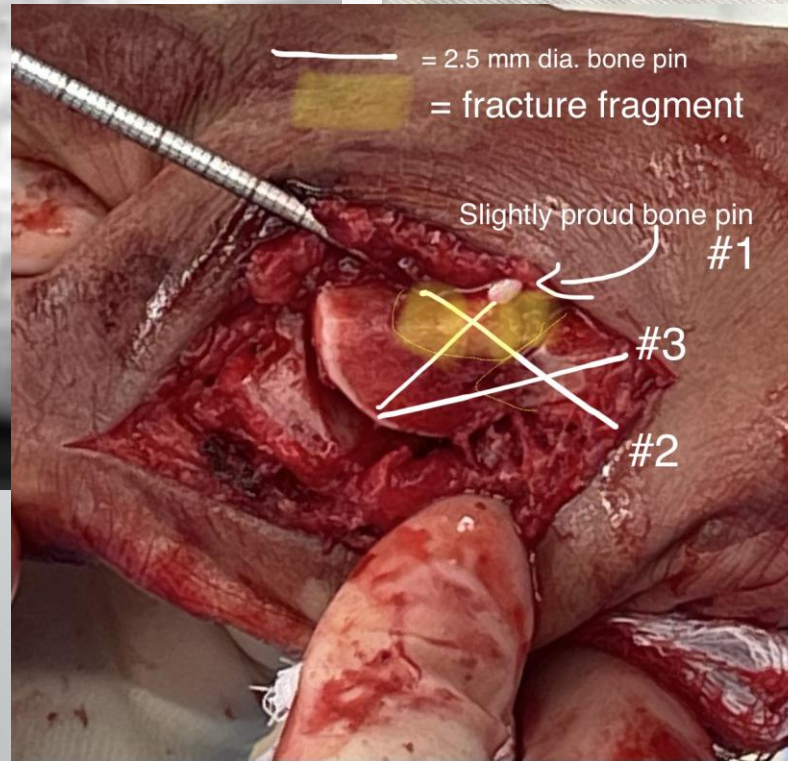
6 Weeks Post-Op



# Iatrogenic Fracture of Austin/Valenti...



Slightly proud AlloMate  
2.5 mm dia. Pin Seen  
Dorsally



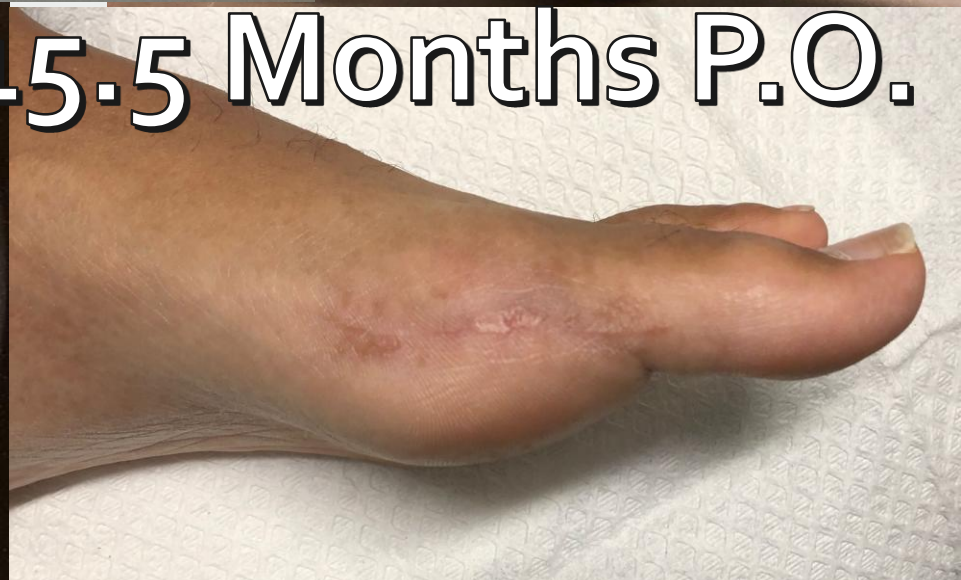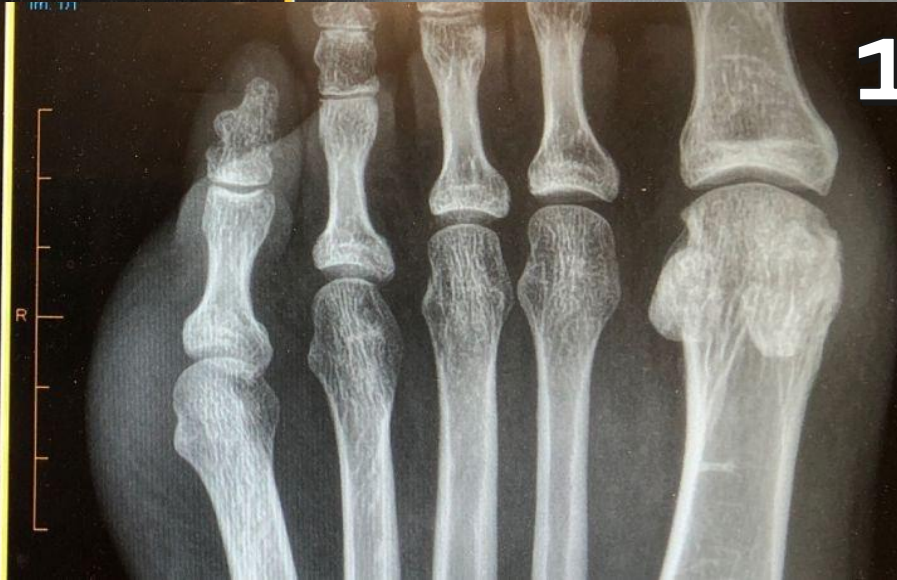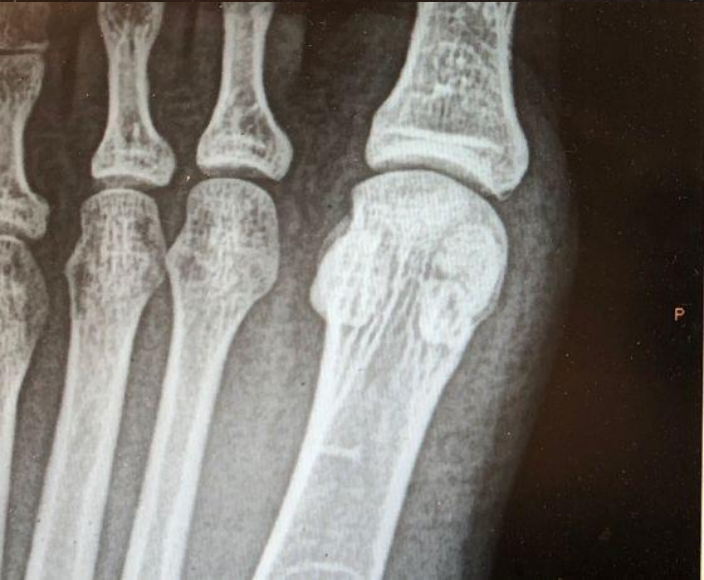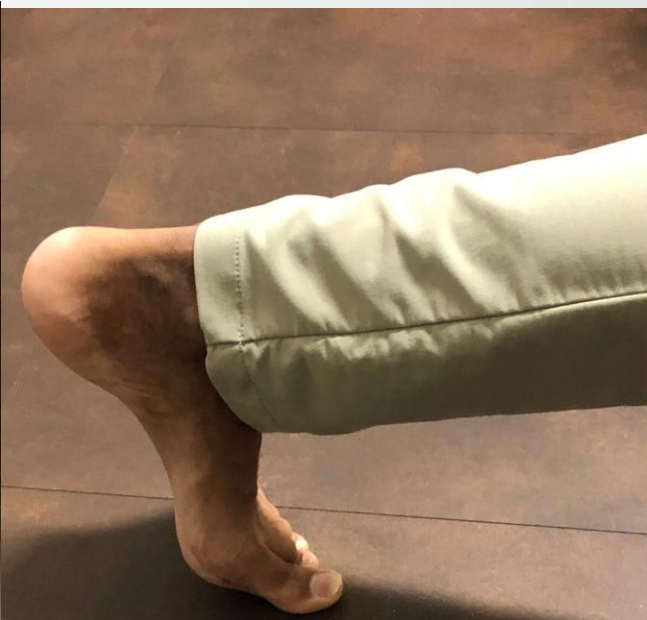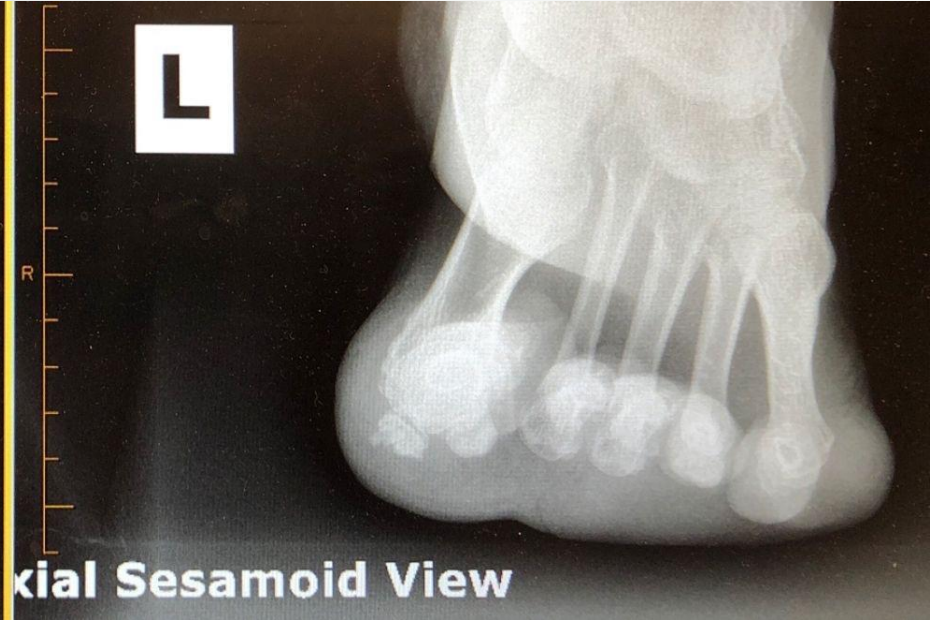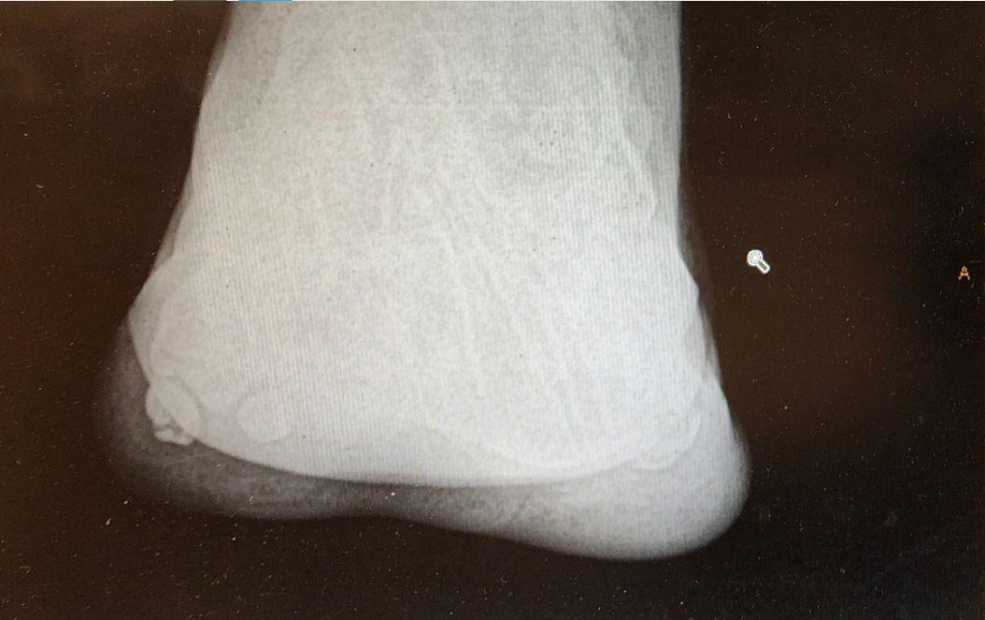— = 2.5 mm dia. bone pin  
— = fracture fragment

Slightly proud bone pin  
#1

#3

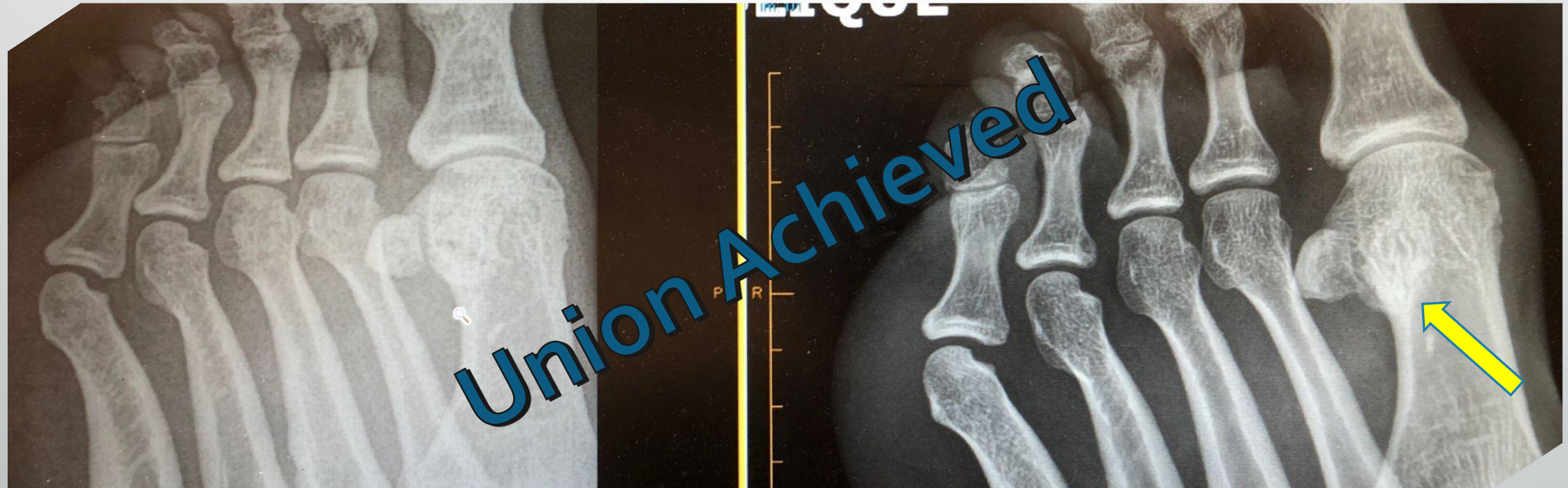
#2

# Non-Union Tibial Sesamoid Fracture

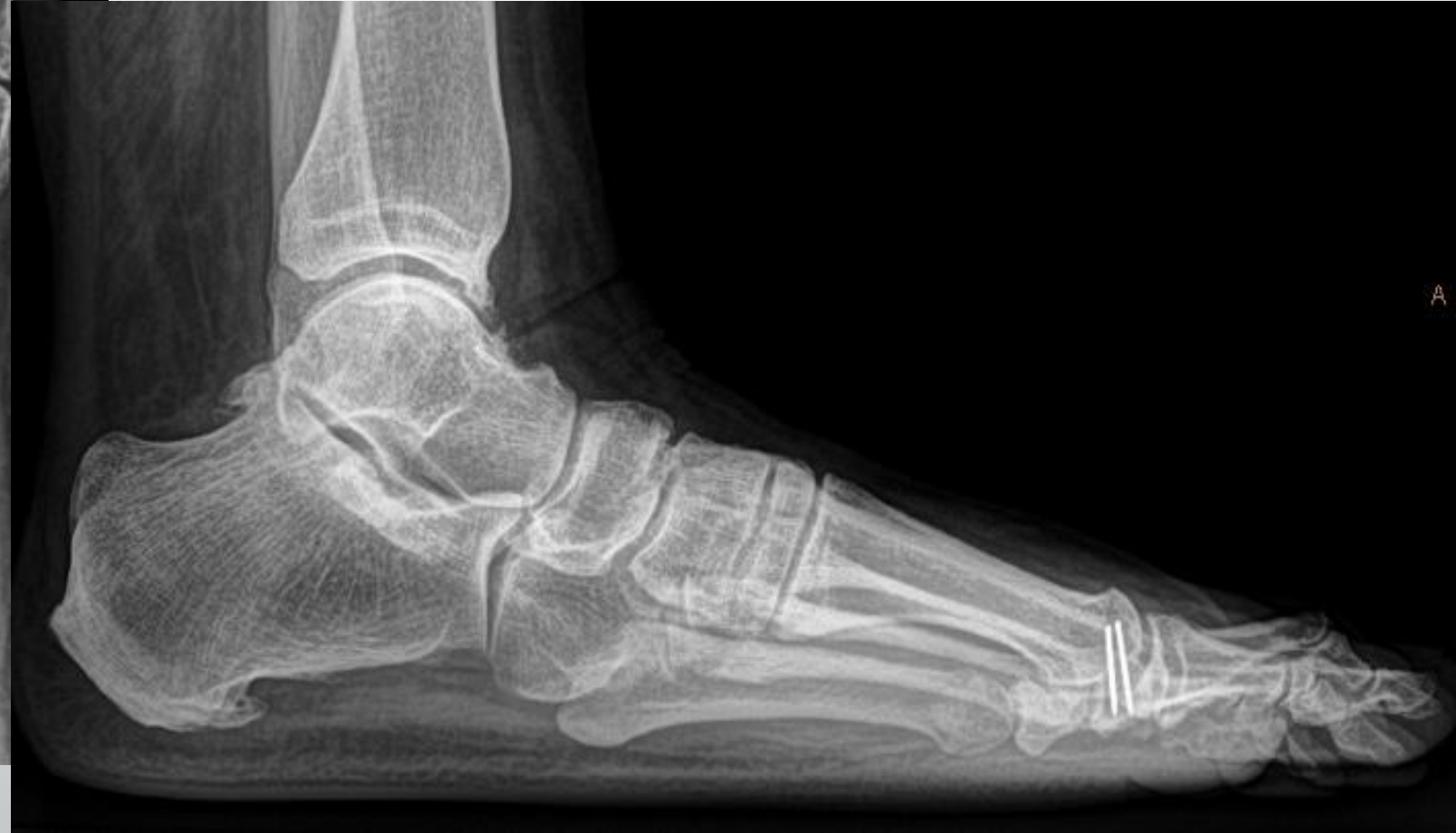
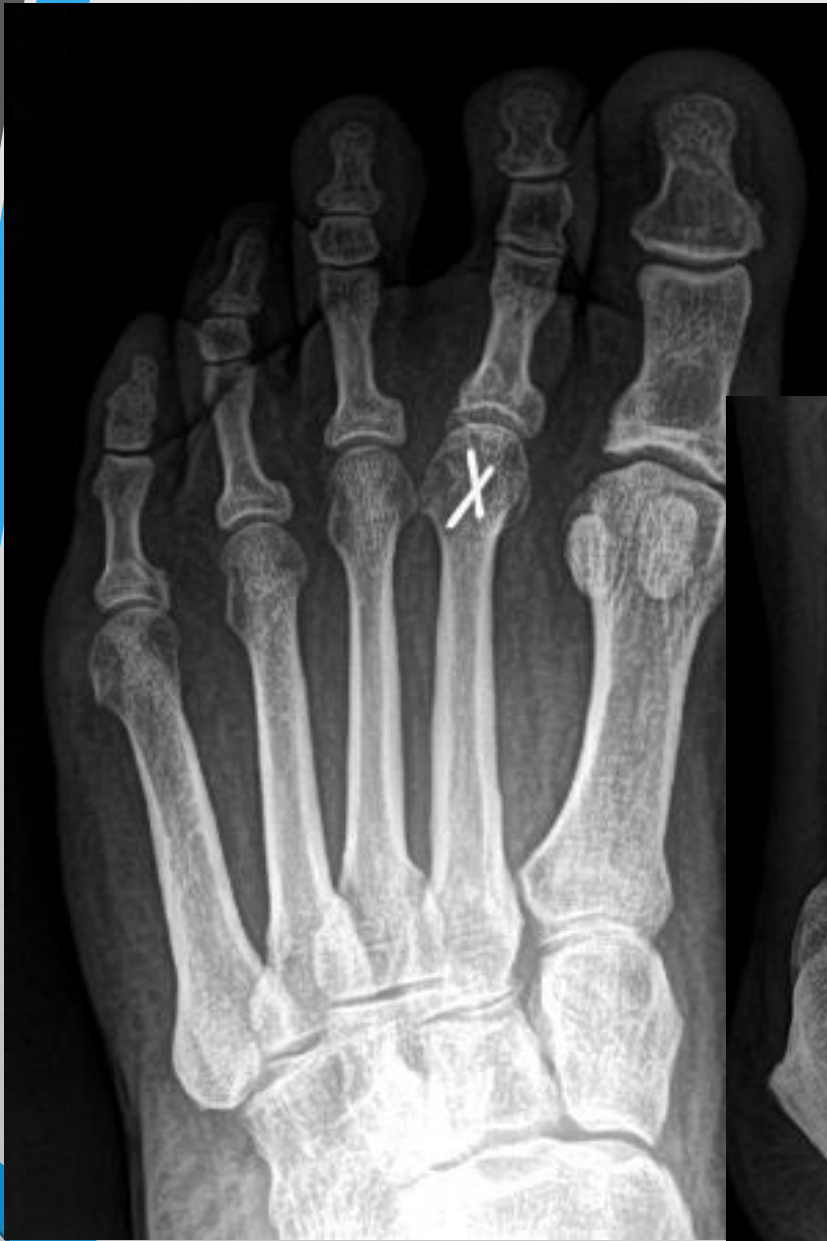
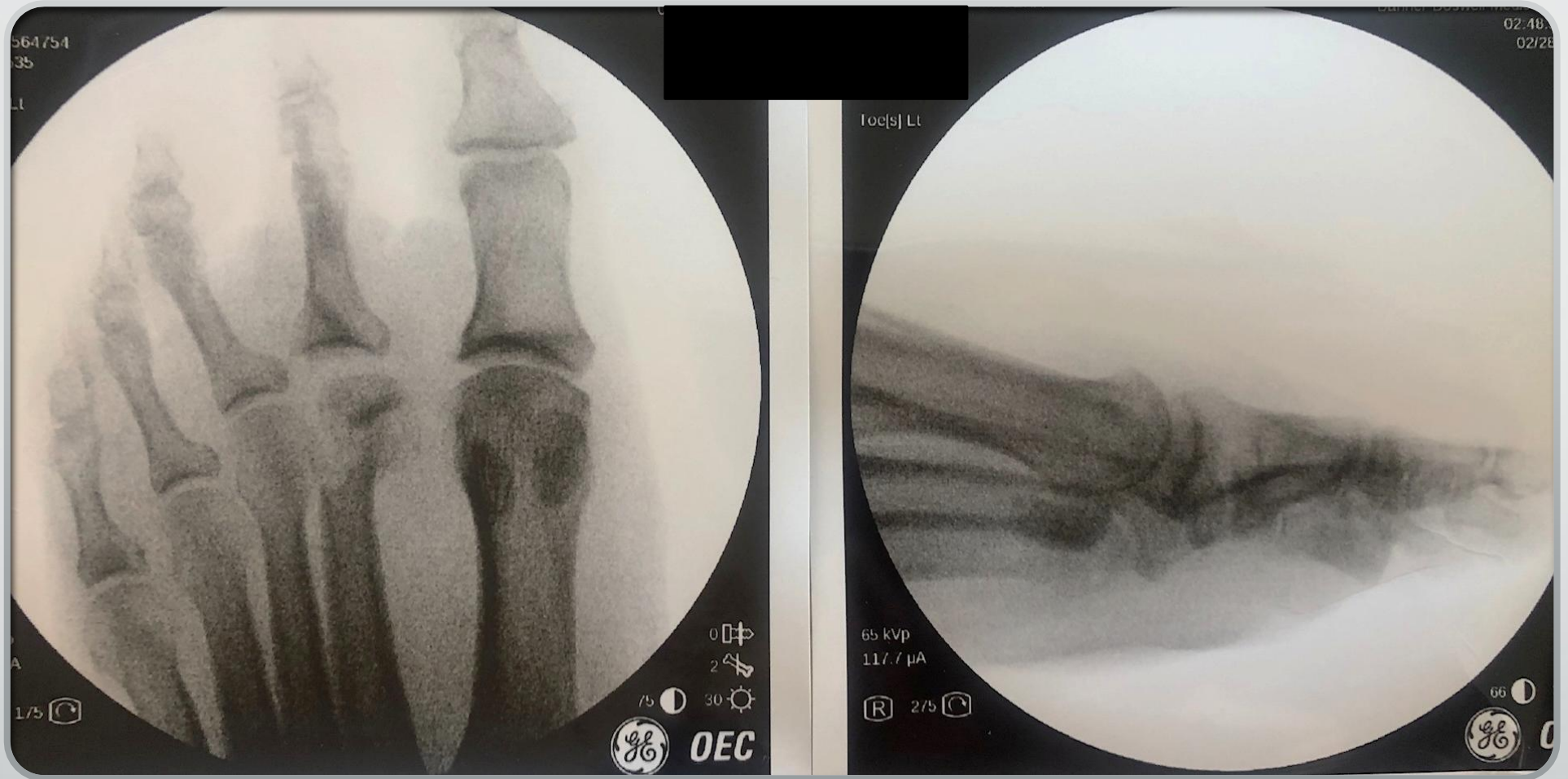
15.5 Months P.O.

# ORIF Non-Union Tibial Sesamoid Fracture



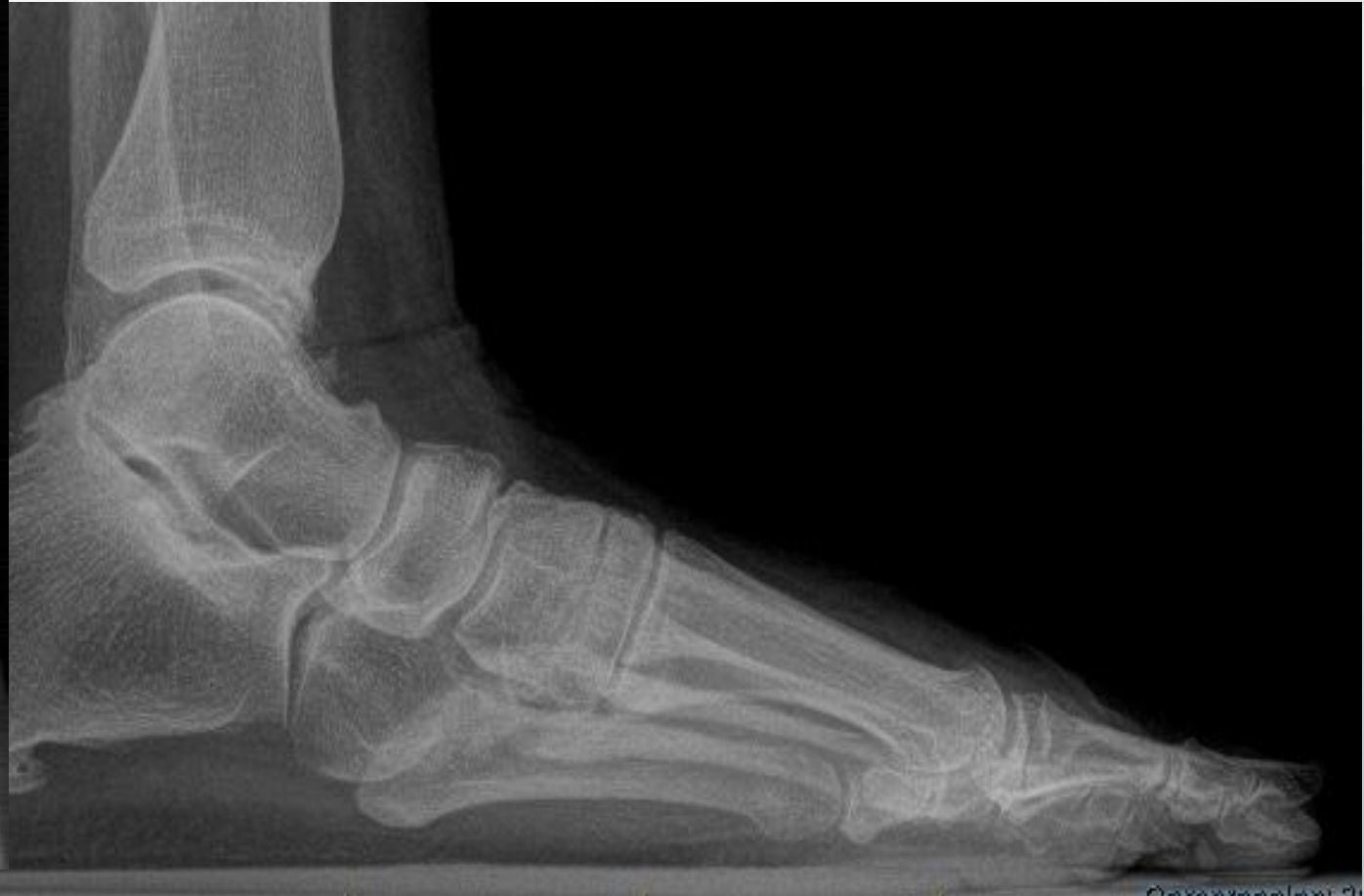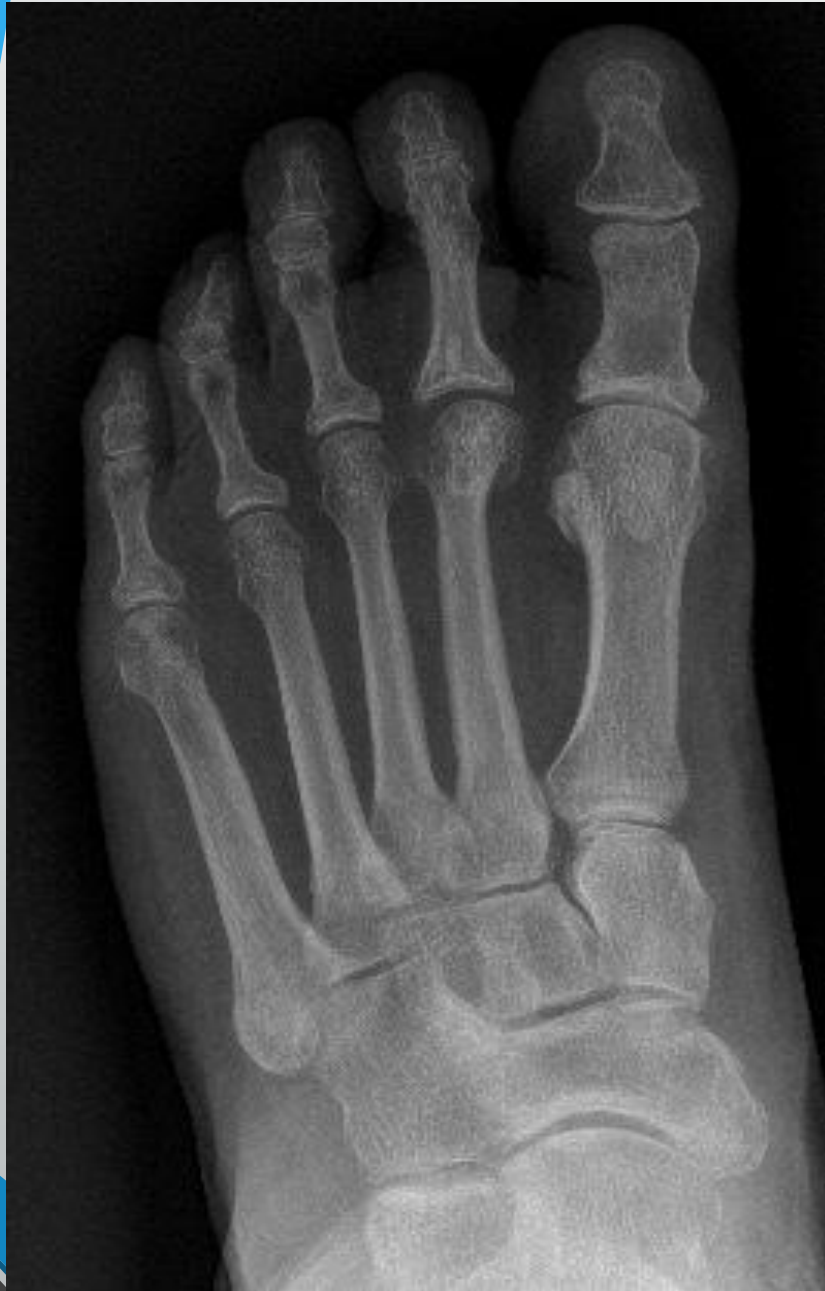# Revision with some challenges...

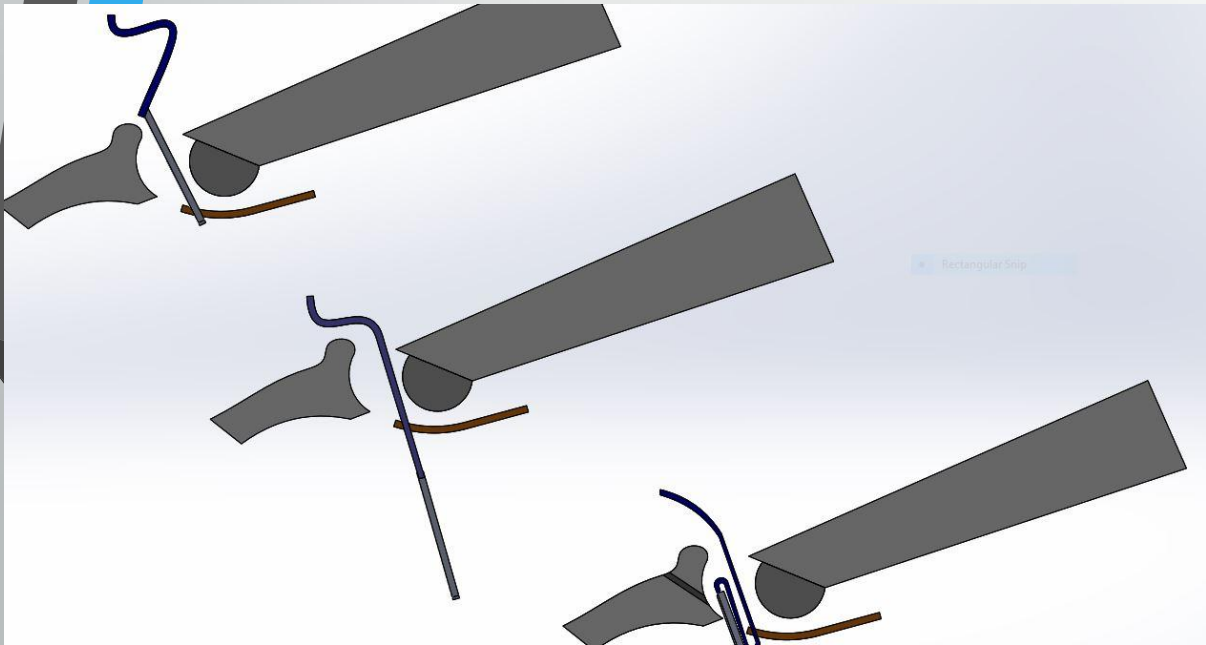
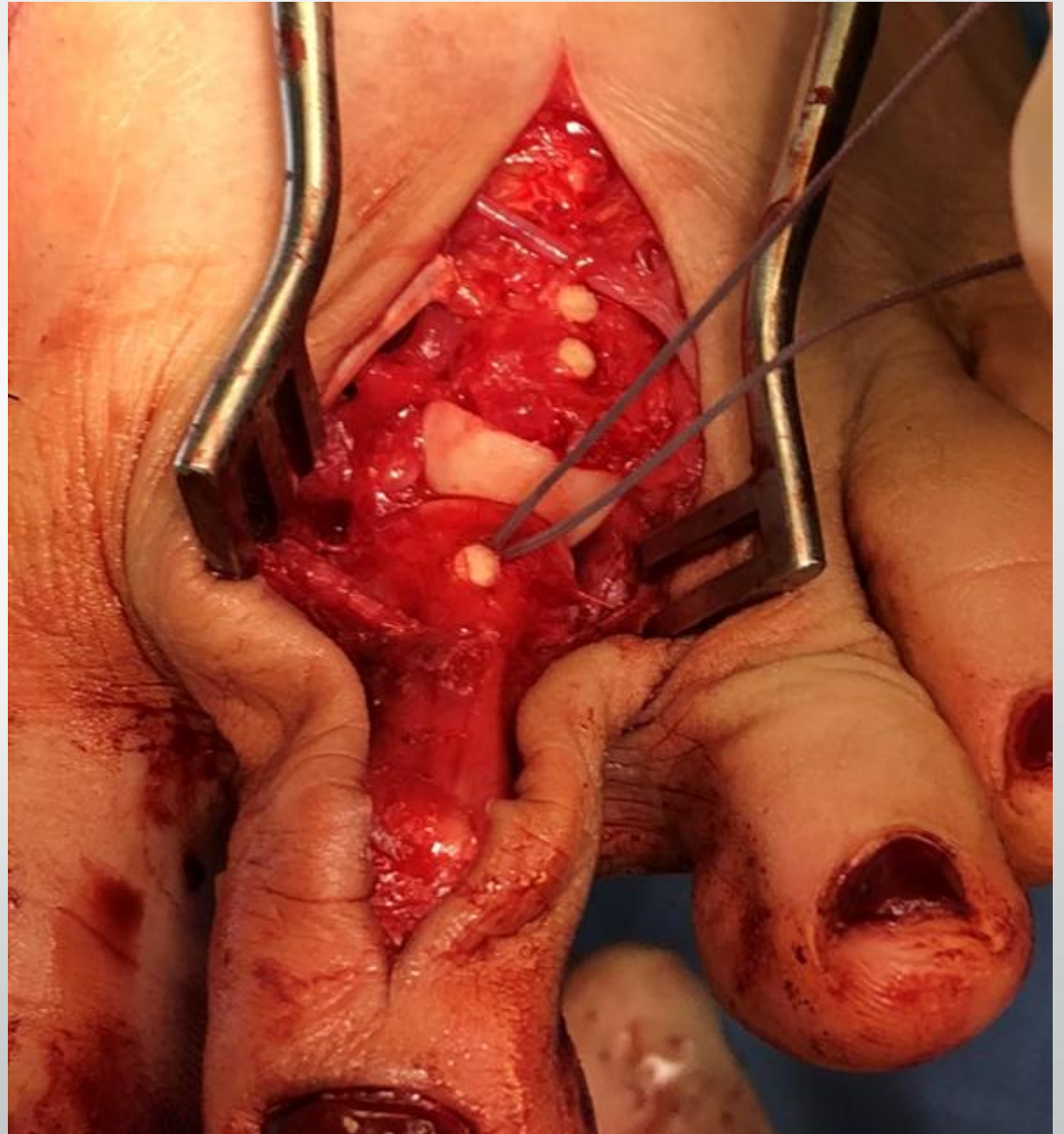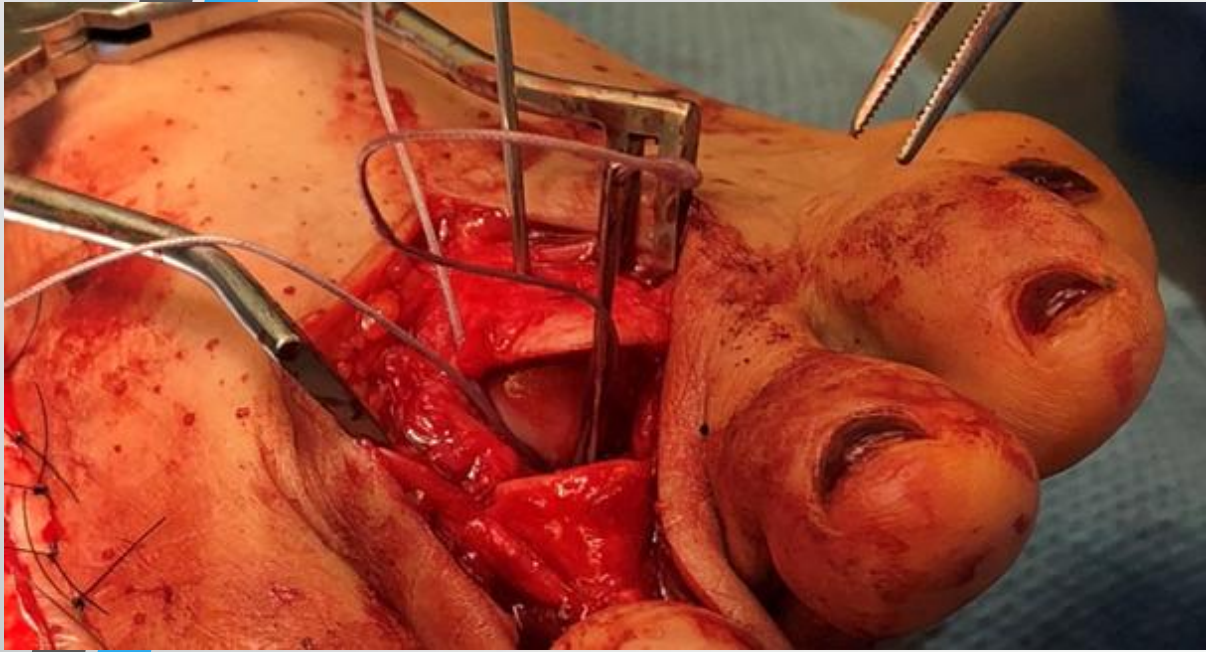




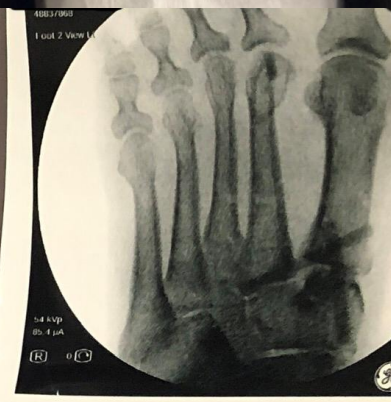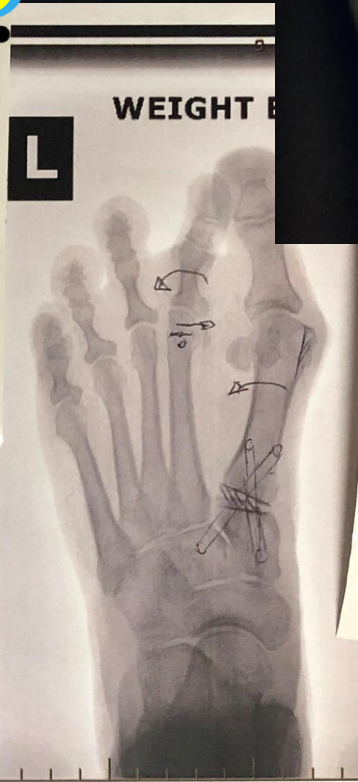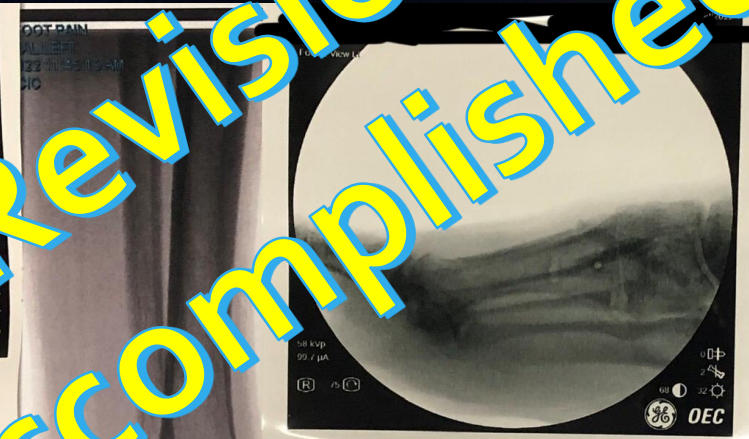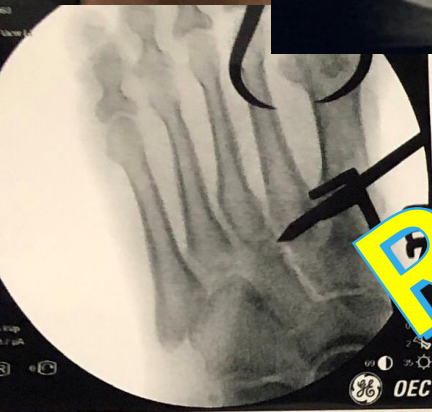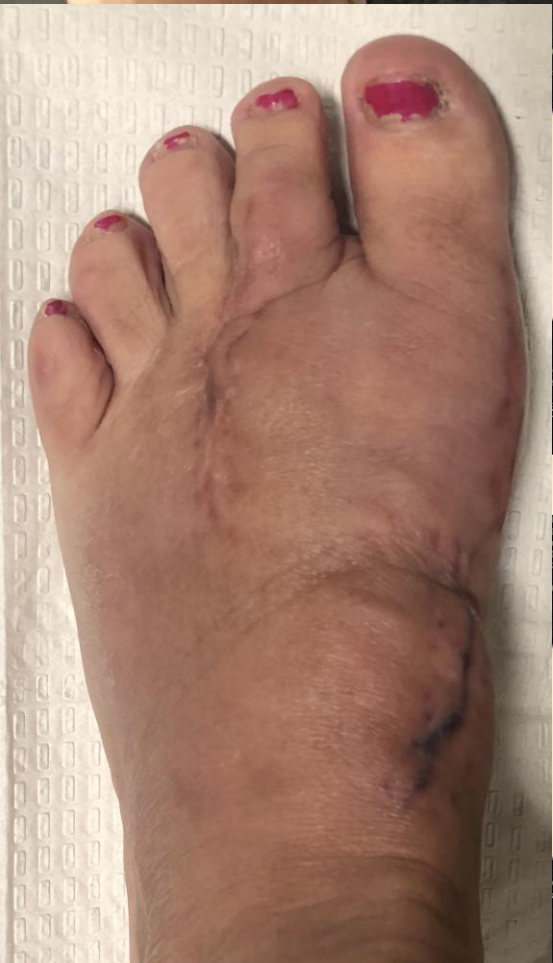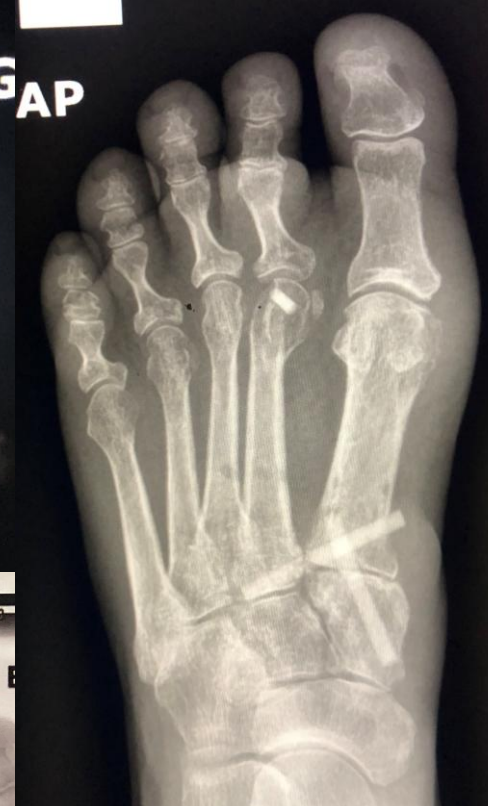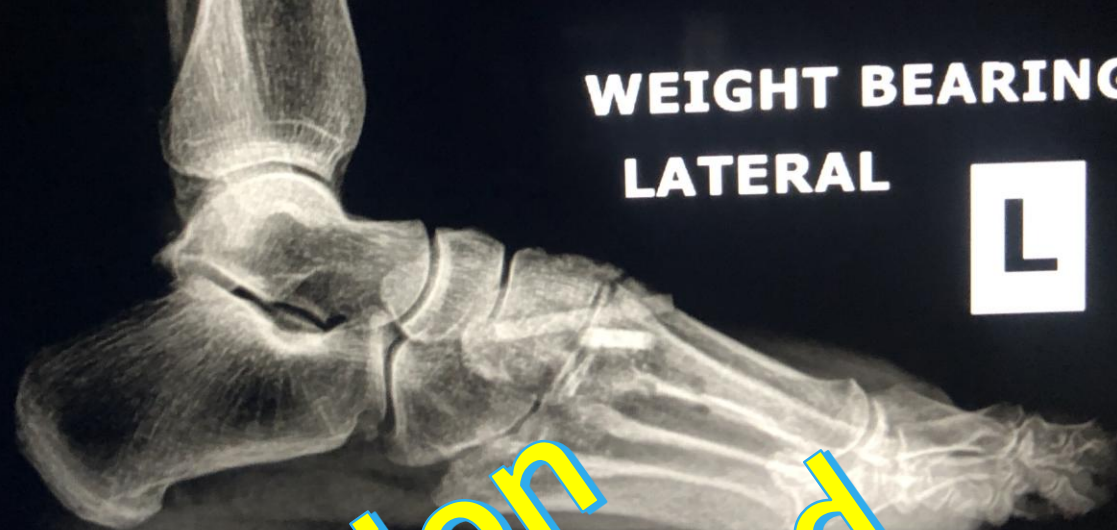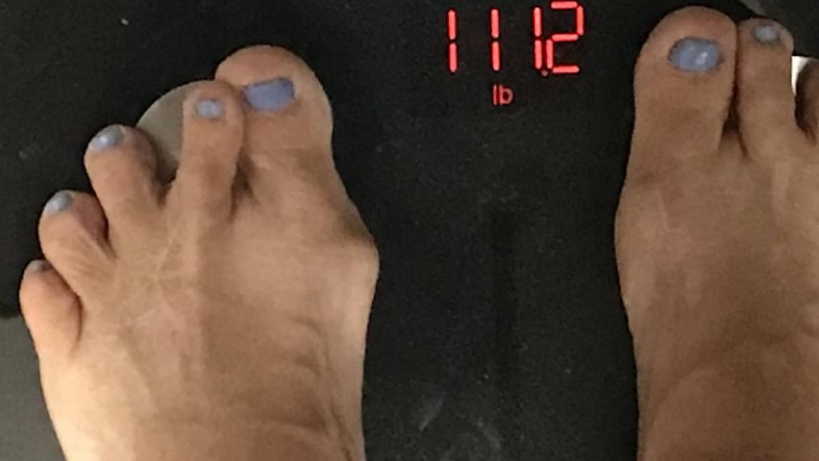# Restored 2<sup>nd</sup> Ray Function and Alignment

# Three Year Postop

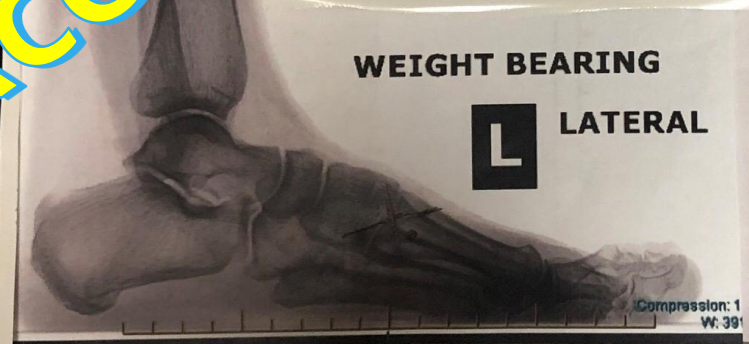


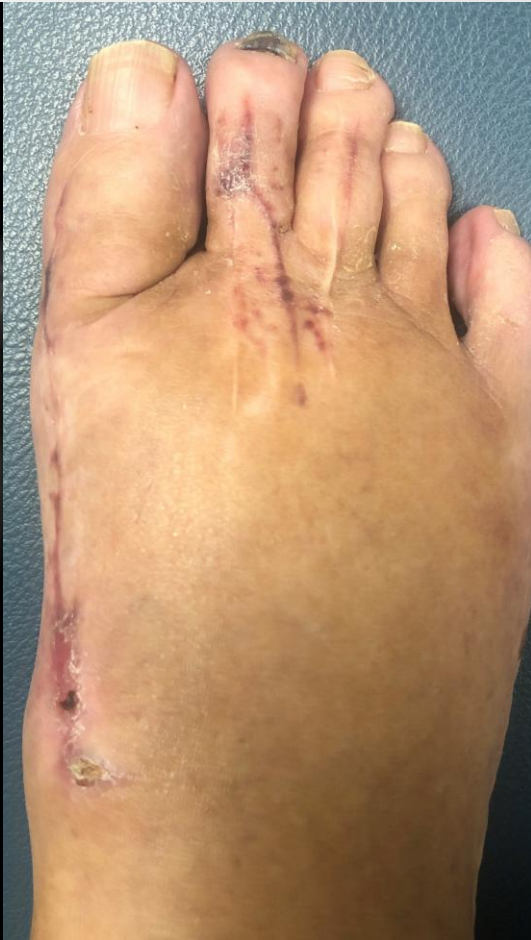
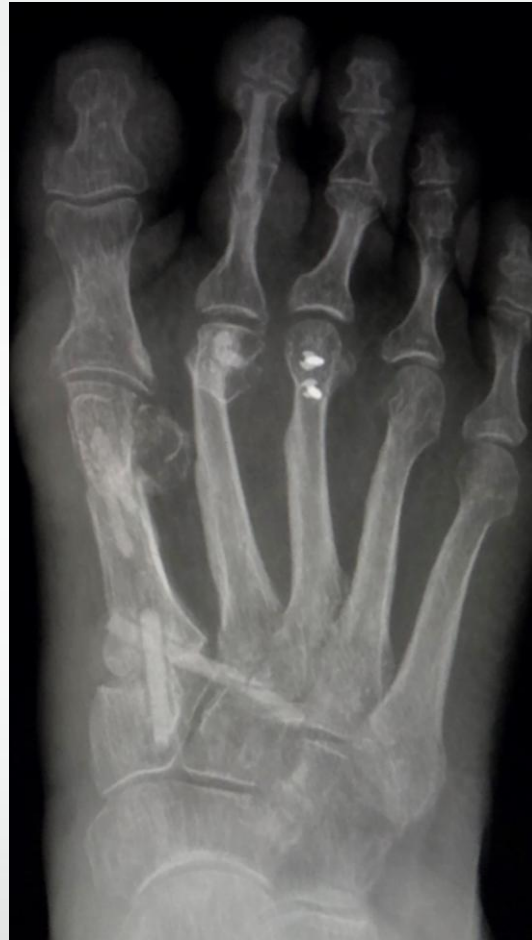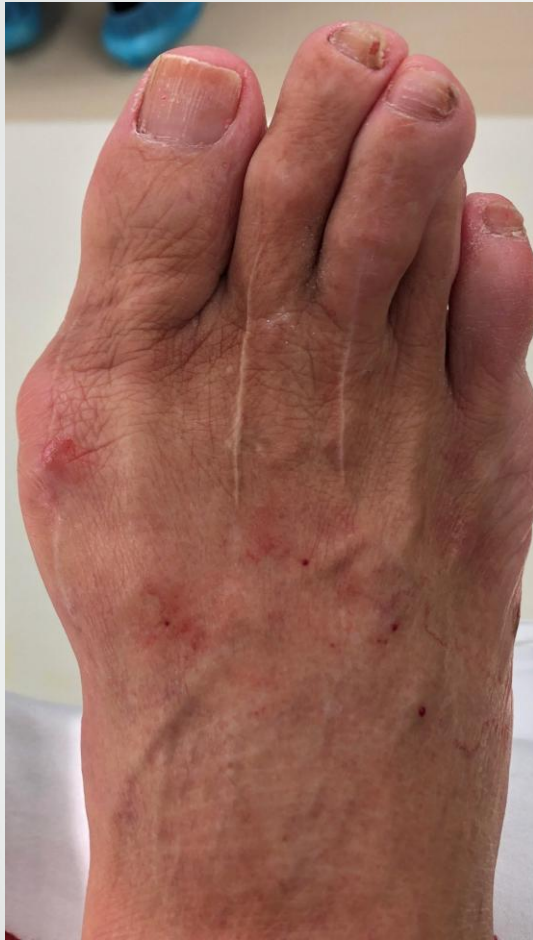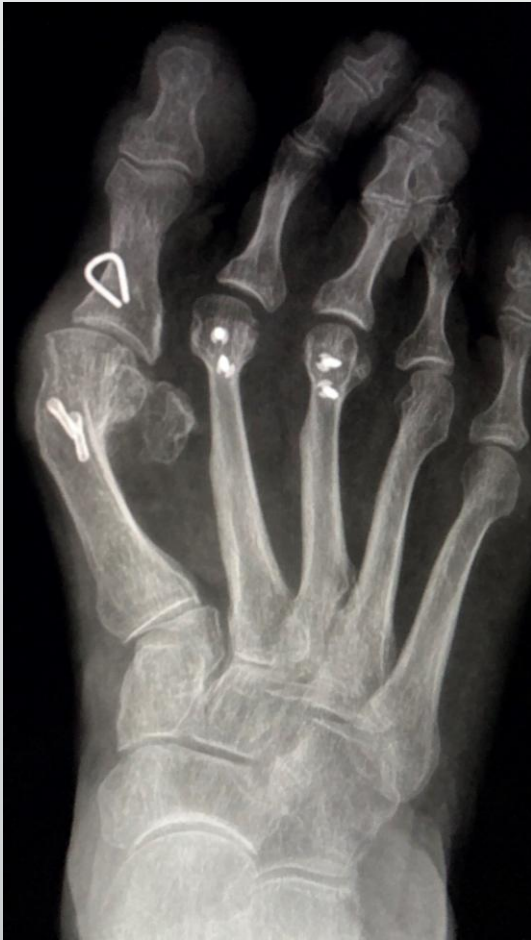112  
lb



Revision  
Accomplished





**“Putting It All Together”  
for Complex Revisions**

# Surgical Pearls:

REMEMBER - Stability always trumps compression.

Technique most important!

Must stabilize osteotomy before inserting allograft cortical bone implant (Don't forget the 15 min Pin Soak!)

Surgical bone remodeling and removal of necessary periosteum is performed before insertion of implant

# **Final Note.....**

*"You may compress  
to impress, but  
you must not  
distract to  
attract."*

***Dr. Schulman***

## REFERENCES

---

Asselmeier MA, Caspari RB, Bottenfield S: A review of allograft processing and sterilization techniques and their role in transmission of the human immunodeficiency virus, *Am J Sports Med*, Mar-Apr 1993; 21(2): 170-5 [Medline]

---

Ford TC, LM Maurer, KW Myick: Cortical bone pin fixation - A preliminary report on fixation of digital arthrodesis and distal chevron first metatarsal osteotomies, *J Foot Ankle Surg* 41:23-29, 2002

---

Horowitz MC, Friedlaender GE: The Immune Response to Bone Grafts, In: Friedlaender GE, Goldberg VM: Bone and Cartilage Allografts – Biology and Clinical Applications, Rosemont, IL: American Academy of Orthopedic Surgeons

---

Kominsky SJ, Bermudez A, Bannerjee A: Using a Bone Allograft to Fixate Proximal Interphalangeal Joint Arthrodesis, *Foot & Ankle Specialist*, March 2013

---

Kumar B, Yilmaz B, Kaan E, Yupei B, Duymus TM, Ozdemir G, Guler O: Mid-Term Results of Two Different Fixation Methods for Chevron Osteotomy for Correction of Hallux Valgus, *J Foot and Ankle Surg* 57(2018) 904-909

---

Liptak JM, Edwards MR, James SP, Dernel WS, Bachand AM, Withrow SJ: Mechanical characteristics of cortical bone pins designed for fracture fixation, *Clin Orthop Relat Res*. 2007

---

Reed TM: Allofix freeze-dried cortical bone pins as an alternative to synthetic absorbable polymeric pins: A preliminary study in short Z bunionectomies, *J Foot Ankle Surg* 38:14-23, 1999

---

Weintraub GM, Daulat R: The Evans Osteotomy: Technique and Fixation with Cortical Bone Pin, *J Foot and Ankle Surg*, Vol. 40, Number 1, January/February 2001

# THANK YOU

